

ORIGINAL ARTICLE

Lumbar myelomeningocele in newborns: a comprehensive guide to open surgical technique

Alberto Ramírez Espinoza¹, Esther Velarde Llerena¹, Yosimar Coasaca Tito¹¹ Sub Unidad de Atención Integral Especializada del Paciente de Neurocirugía, Instituto Nacional de Salud del Niño San Borja, Lima, Peru.

ABSTRACT

Myelomeningocele (MMC) represents a primary failure of neurulation, the process through which the neural tube forms, leading to the exposure of the spinal cord segment at the patient's back. It is considered the most severe malformation of the central nervous system compatible with life, typically occurring between days 20 to 28 of gestation. The incidence of myelomeningocele ranges approximately from 0.7 to 0.8 per 1000 live births, a rate that varies depending on the region. Achieving surgical treatment and complete closure of myelomeningocele pose significant challenges, as does its postoperative evolution without complications. Various surgical techniques have been described for myelomeningocele closure, ranging from simple to more complex approaches. In this study, we provide a step-by-step description of a surgical technique employed for treating a newborn patient diagnosed with MMC. We consider that this technique can be applied to both simple and complex myelomeningoceles.

Keywords: Myelomeningocele; Infant, Newborn; Spinal Dysraphism (Source: MeSH)


Cite as:

Ramírez Espinoza A, Velarde Llerena E, Coasaca Tito Y. Lumbar myelomeningocele in newborns: a comprehensive guide to open surgical technique. *Investig Innov Clin Quir Pediatr.* 2024;2(1):25-34. doi:10.59594/iicqp.2024.v2n1.79

Corresponding author:

Alberto Ramírez Espinoza
Address: Av. Javier Prado Este 3101,
San Borja, Lima
E-mail: alberto386@hotmail.com

ORCID iDs

Alberto Ramírez Espinoza
 <https://orcid.org/0000-0003-3530-5704>
Esther Velarde Llerena
 <https://orcid.org/0009-0008-3617-8915>
Yosimar Coasaca Tito
 <https://orcid.org/0009-0005-6161-3657>

Received : 03/17/2024

Accepted : 03/27/2024

Published : 04/23/2024



This publication is licensed under a Creative Commons Attribution 4.0 International License.

Copyright © 2024, Investigación e Innovación Clínica y Quirúrgica Pediátrica.

Mielomeningocele lumbar en recién nacido: descripción paso a paso de la técnica quirúrgica abierta

RESUMEN

El mielomeningocele (MMC) representa la falla primaria de la neurulación (proceso por el cual se forma el tubo neural) que resulta en la exposición del segmento de la médula espinal a nivel de la espalda del paciente. Es considerada la malformación más severa del sistema nervioso central compatible con la vida, ocurriendo durante los días 20 a 28 de gestación. Su tratamiento quirúrgico y cierre completo es un reto, así como su evolución sin complicaciones en el postoperatorio. Se han descrito diferentes técnicas quirúrgicas para el cierre del mielomeningocele, desde técnicas simples hasta las más complejas. En el presente estudio describimos paso a paso la técnica quirúrgica utilizada por los autores para el tratamiento de un paciente recién nacido diagnosticado con MMC. Consideramos que esta técnica puede ser aplicada tanto a los mielomeningoceles simples como complejos.

Palabras clave: Mielomeningocele; Recién Nacido; Disrafia Espinal (Fuente: DeCS)

INTRODUCTION

Myelomeningocele (MMC) is a devastating congenital neural tube defect for which there is no cure to date. It consists of protrusion of the meninges and spinal cord (placode) through open vertebral arches (dysraphism), leading to intellectual and physical disabilities, including paralysis, depending on its location and severity. In addition, patients with MMC may have bowel dysfunction, bladder dysfunction, and orthopedic disabilities. The etiology of MMC remains poorly understood, but the primary failure of the neural tube or mesenchymal closure at the caudal neuropore in the embryonic period results in exposure of the placode in the uterine environment. During fetal development, the placode may be vulnerable to damage from trauma or amniotic fluid, leading to secondary destruction of neural tissue. Until a decade ago, treatment of MMC consisted of surgical closure of the spinal canal at

birth and lifelong supportive care. Recent studies suggest that intrauterine repair can mitigate neurological dysfunction, reduce morbidity related to hydrocephalus, and mitigate the occurrence of Arnold-Chiari II malformation—a condition characterized by the protrusion of cerebellar tissue into the spinal canal—by reversing the herniation of cerebellar tonsils through the foramen magnum (1,2).

Technological advances in prenatal diagnosis now allow diagnosis of CMM as early as the first trimester of gestation, and extensive research into the etiology of neural tube defects has raised the various genetic and micronutrient causes (3). There has been significant progress in preventing this disorder through folic acid supplementation, which has only reduced the incidence. Even with aggressive intervention, about 14 % of all newborns with spina bifida do not survive beyond 5 years, with mortality increasing to 35 % in those with symptoms of brainstem dysfunction secondary to Arnold-Chiari II malformation (4). Even 70 % of patients have an IQ of >80, and approximately 50 % can live with a degree of independence as adults, even with adapted activities (5). Due to its characteristics, this disease has an emotional and economic impact on the patient's family and social environment. In 1994, the cost of care for all patients with CMM in the United States exceeded \$500 million annually (2,6).

The most important and demanding complications in CMM are hydrocephalus, Arnold Chiari II malformation and tethered cord at the site of surgical repair. Hydrocephalus, defined as increased dimensions of the cerebral ventricles, occurs in more than 85 % of patients with CMM. Approximately 80 % of patients with spina bifida require a ventricular cerebrospinal fluid shunt to decrease the neurological and intellectual compromise that accompanies hydrocephalus, and 46 % of these patients may have shunt complications within the first year after the procedure (2,6,7). The ideal time for postnatal open surgery is the first 48 to 72 hours after birth and the surgical treatments are fetal surgery and postnatal open surgery (7). The aim of the present study is to describe step by step the postnatal open surgical technique used by the authors in the Neurosurgery Department of the Instituto Nacional de Salud del Niño San Borja. This technique, according to our experience, minimizes spinal tissue injury, decreases the chances of cerebrospinal fluid fistula and ventriculitis, and prevents subsequent problems with the operative wound.

DESCRIPTION OF THE SURGICAL TECHNIQUE

Position of the patient

After starting general anesthesia and with the patient intubated, the patient is placed in ventral decubitus with rotation of the head in the direction of the anesthesia ventilator, to facilitate intraoperative monitoring by the anesthesiologist. The dorsolumbar region must be completely horizontal to facilitate the symmetrical reconstruction of the tissues (Figure 1).

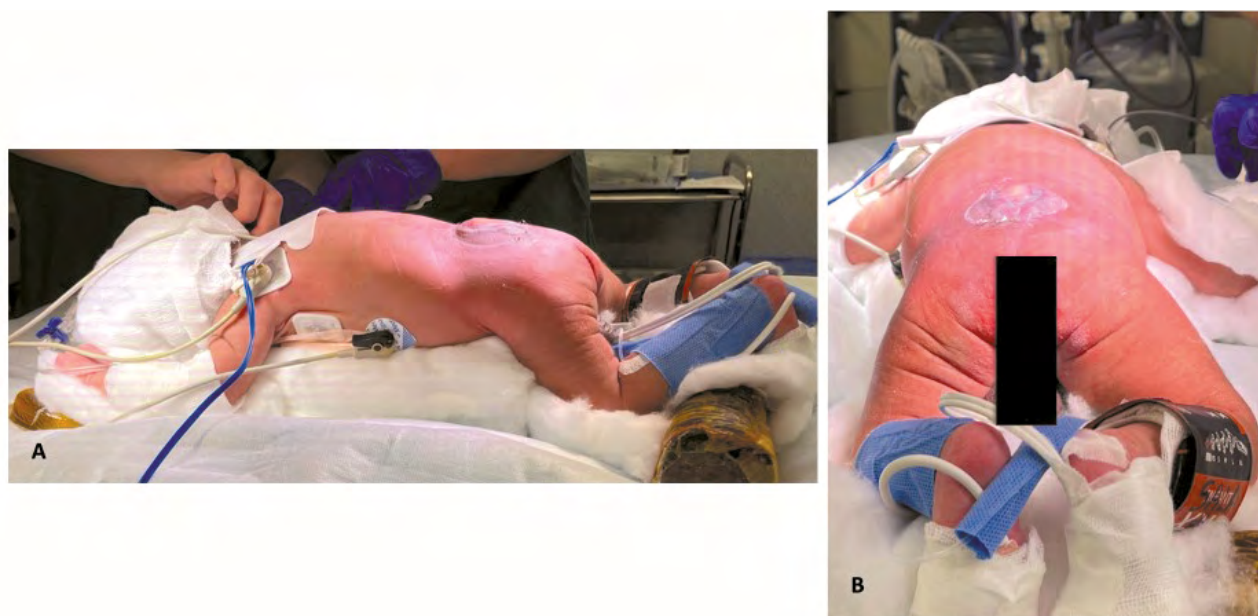

Figure 1. Surgical positioning of the patient with lumbar myelomeningocele. A. Prone decubitus position with the protection of support areas, avoiding pressure injuries, and facilitating optimal management by anesthesiology while maintaining control of the patient's temperature. A. This view shows the dorsal lumbar region flat and level. B. Anteroposterior view.

Incision and dissection of the placoplasty

Once the patient is in the surgical position, the preoperative lavage with 2% chlorhexidine is performed, the surgical drapes are placed and the safe surgery checklist is carried out. The surgery begins with the use of the surgical microscope and microsurgical instruments. The limit of the placoplasty with the dysplastic skin is identified: it is at this limit where the surgery begins. The incision is made with a scalpel N° 11 until the cerebrospinal fluid is released. At this moment samples can be taken for cytochemical studies and cultures. It is important to control blood loss in newborns, so much attention is paid to hemostasis. Through the first incision the spinal dura mater and the nerve roots of the lumbosacral plexus are visualized. At this point the incision is widened, using microsurgical scissors, surrounding the placode and visualizing the presence of nerve roots, so that they remain intact and in their medial position (Figure 2).

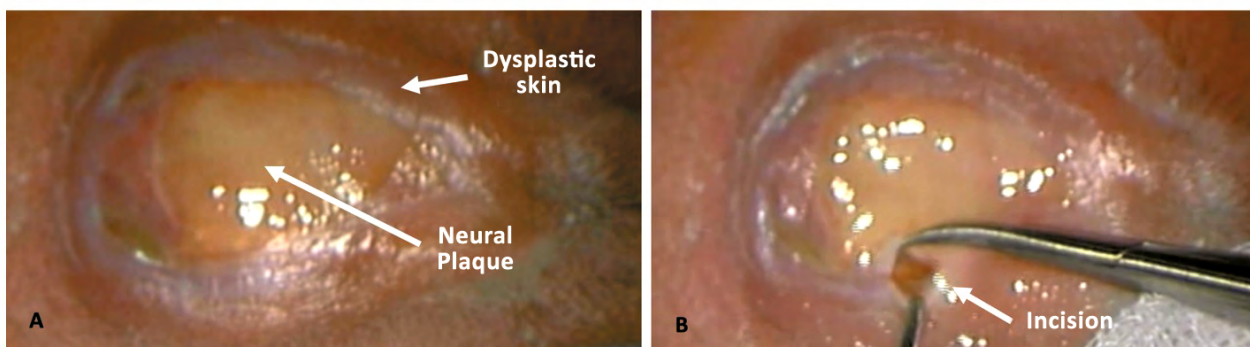


Figure 2. Images of the lumbar myelomeningocele under the surgical microscope. A. Neural plaque and dysplastic skin. B. Beginning of surgery at the border between the neural plaque and dysplastic skin, with verification of cerebrospinal fluid outflow.

Microsurgical dissection of the sacculle proceeds, ensuring the preservation of the border with the dysplastic skin and avoiding harm to any nerve roots that might be attached to the dural sac via arachnoid tissue. Continuing with the dissection, the boundary between the spina bifida and the normal spinal canal becomes apparent. At this juncture, the spinal cord and the motor roots emerging from the sacculle are observable. Dissection continues until the placode is entirely isolated from the dysplastic skin (Figure 3).

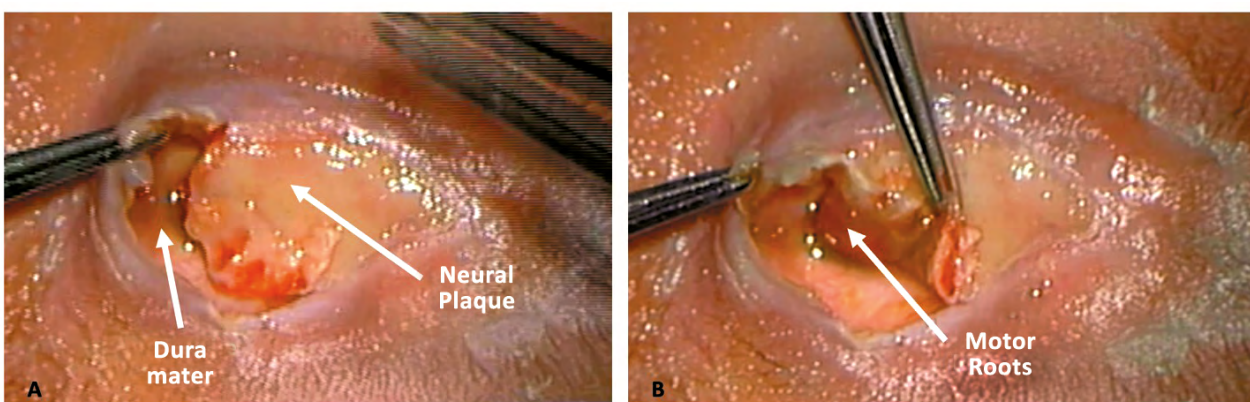


Figure 3. Neural placode dissection. A. Dural sac with the presence of cerebrospinal fluid. B. Motor roots preserved during microsurgical dissection

Tubulization of the placode

Once the dissection of the placode is finished and no dysplastic skin remains attached, tubulization and reconstruction of the neural tube commence. This process involves using separate stitches (5/0 non-absorbable suture with a 13 mm 3/8 round needle) to appose the edges of the dura until complete closure of the defect is attained, mimicking the anatomy of the spinal cord. It's important to exercise caution to avoid including nerve roots or other tissues during suturing (Figure 4).

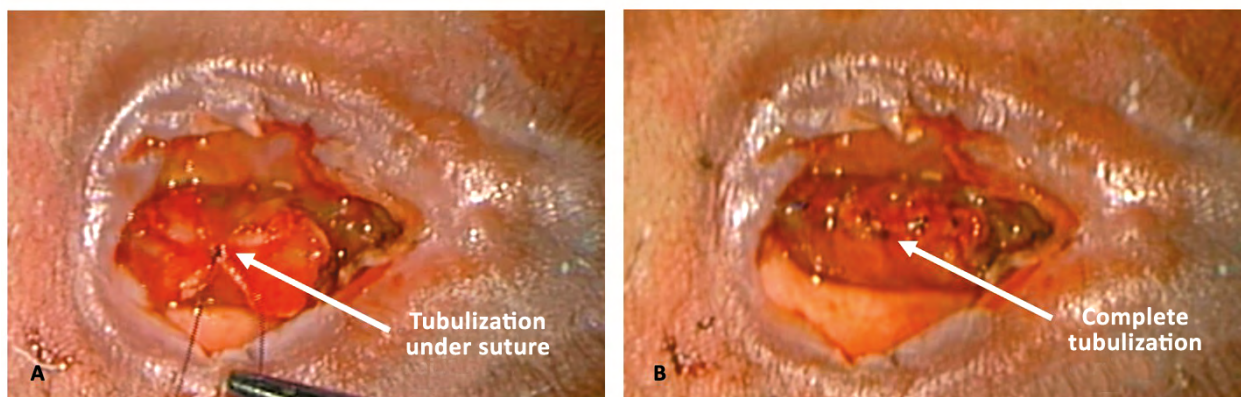


Figure 4. Once the dissection of the neural placode is completed, the reconstruction of the neural tube begins. A. Suture of the neural placode from the outermost edge with single, separate stitches. B. Complete tubulization with single, separate stitches. The dura mater with cerebrospinal fluid can be seen on the sides.

To initiate the dissection of the dura mater, we must have a complete exposure of the defect. This involves making incisions in the dysplastic skin at the proximal and distal levels of the defect using a N° 11 scalpel blade, ensuring these incisions follow the spinal midline. The length of the incisions is only as much as necessary to reach the boundary between the dysplastic skin and the normal skin. Manipulation of the dysplastic skin can be conducted without fear of damage as it will ultimately be removed (Figure 5).

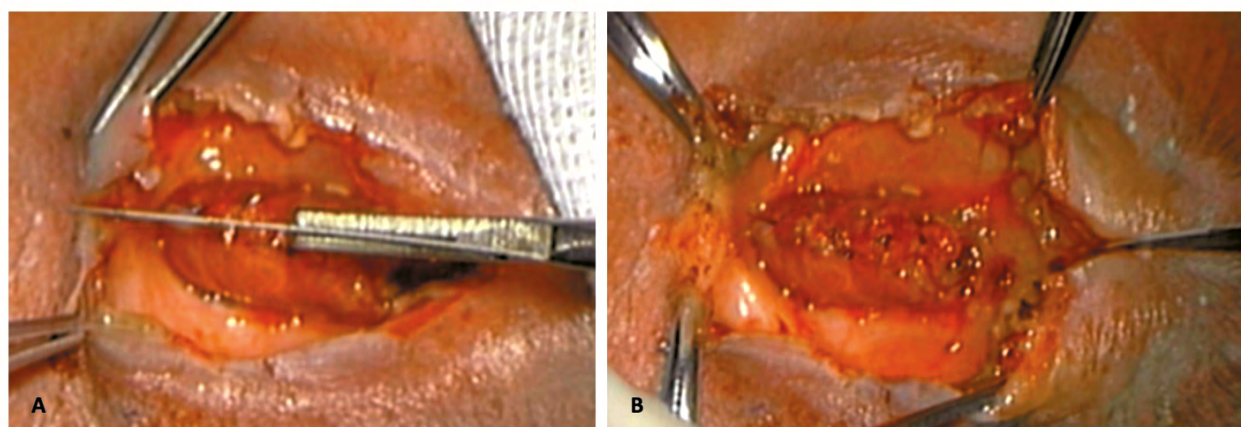


Figure 5. Incision of the dysplastic skin at its ends using scalpel blade N° 11. A. Shows the proximal end of the defect at the medial level. B. Displays the distal end of the defect at the medial level.

The nerve roots are freed from the arachnoid tissue that anchors them to the dura mater, enabling visualization of the spinal canal and facilitating the anterior movement of the reconstructed plaque, thereby preventing restriction of the duroplasty (refer to Figure 6).

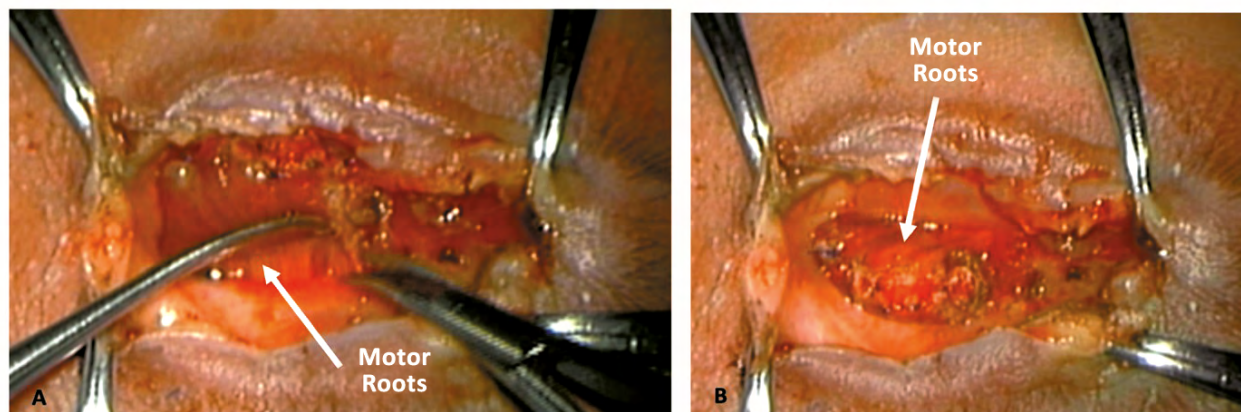


Figure 6. Dissection of the arachnoid connecting the motor roots to the dural sac, facilitating the descent of the tubularized plaque. A. Left motor roots. B. Right motor roots. This maneuver enables the descent of the tubularized plaque.

Dural Dissection and Plasty

Having reconstructed the neural tube, the dura is sought laterally, very close to the dysplastic skin. It is important to ensure that there is enough dura mater tissue to complete the dural plasty. A band of dura mater is preserved, which will serve as a galea, so that the skin can be approximated and the defect can be completely closed, without the need for mobilization of adjacent skin flaps, which would add another morbidity factor, such as incisions and consequently additional scars, potentially unaesthetic and painful. To perform the dura mater plasty, using monopolar electrocautery, an incision is made lateral to the defect, until the paravertebral aponeurosis is observed. Between the dura mater and the paravertebral aponeurosis there is an anatomical plane that facilitates dissection and section of the dura mater using curved Metzenbaum scissors (Figure 7).

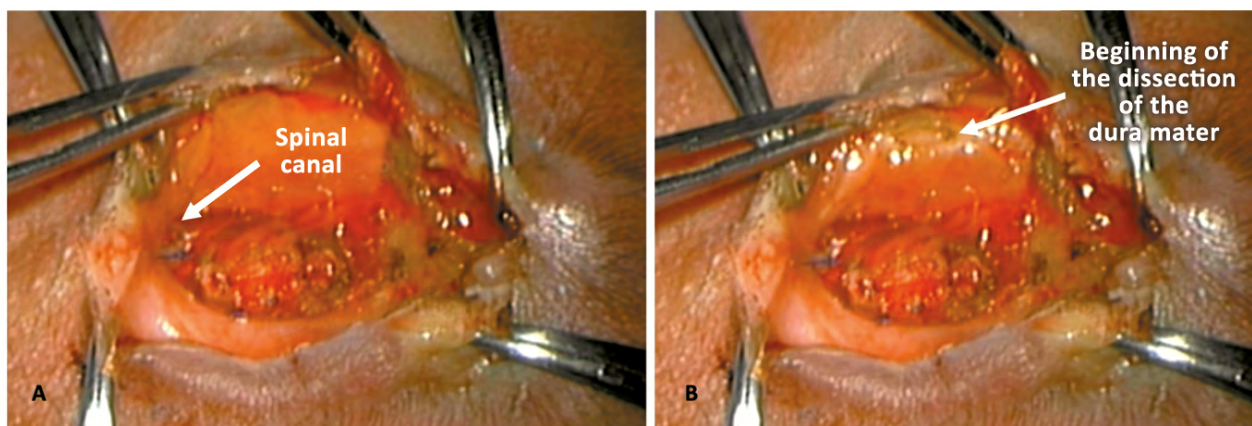


Figure 7. Dural sac dissection. A. Tubularized neural plaque, with the spinal canal visible at the upper end. B. Dissection of the dural sac, conducted as laterally as possible and in proximity to the dysplastic skin.

The dissection and cutting of the dura are carried out using curved Metzenbaum scissors to ensure a uniform section without jagged edges, thereby preventing the formation of cerebrospinal fluid fistulas. The incision extends to the superior and inferior midlines. At the proximal end, the incision is made until it reaches above the beginning of the spinal canal (Figures 8 and 9).

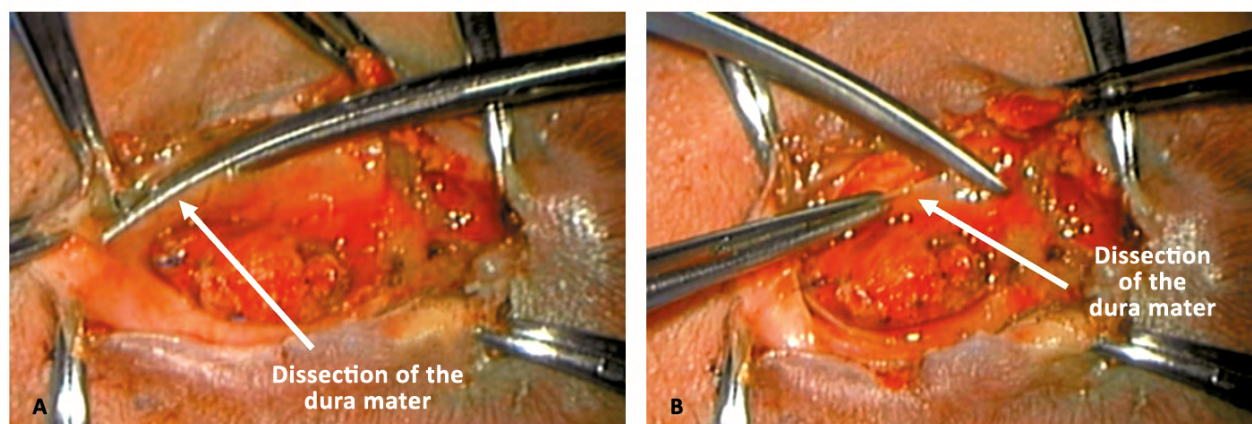


Figure 8. Dural sac dissection: A. Dissection of the dura mater in a proximal and medial-proximal direction should be done as much as possible in a single cut. Multiple or jagged cuts should be avoided to prevent the formation of cerebrospinal fluid fistulas. B. Dissection of the dural sac in a distal and medial-distal direction.

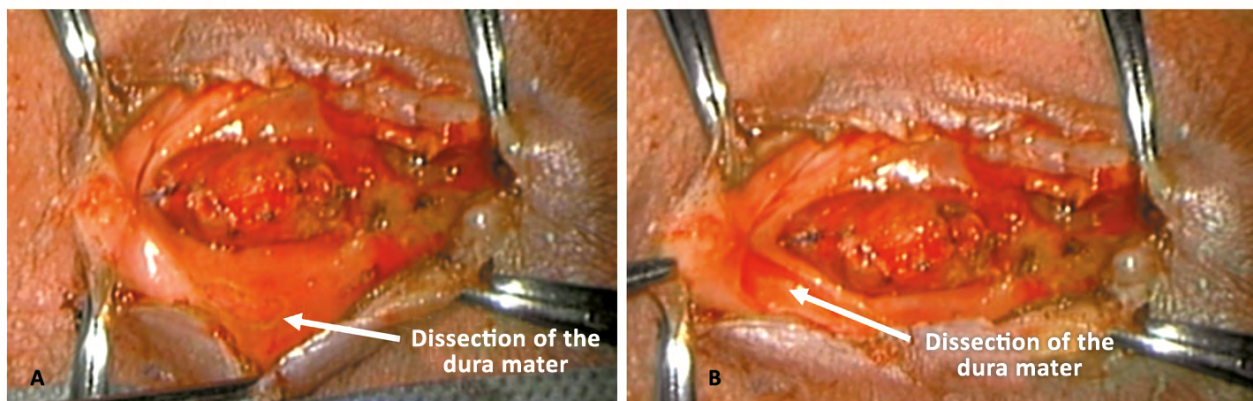


Figure 9. Dural sac dissection. A. Dissection of the dura mater on the contralateral side. B. Complete dissection of the dural sac in its upper half.

Once the dissection of the dura mater is completed, duroplasty is performed. Initially, separate stitches are used with 5/0 polypropylene suture and a 13 mm 3/8 round atraumatic needle to maintain the symmetry of the dura mater, thus preventing potential cerebrospinal fluid leakage from any inadequately addressed edge of the dura mater (refer to Figures 10 and 11).

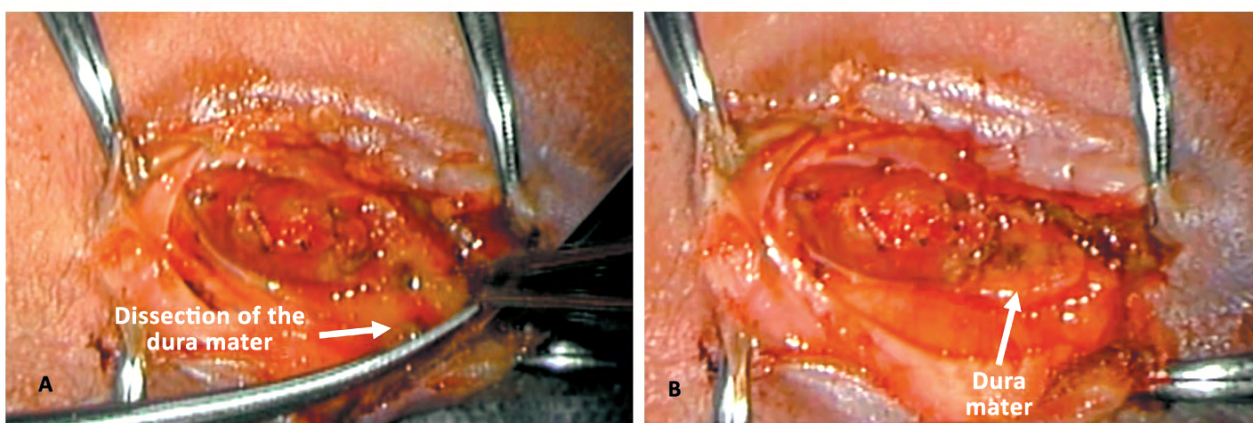


Figure 10. Dural sac dissection. A. Dissection of the dura mater on the inferior opposite side until it joins with the contralateral border. B. Complete dural sac dissection.

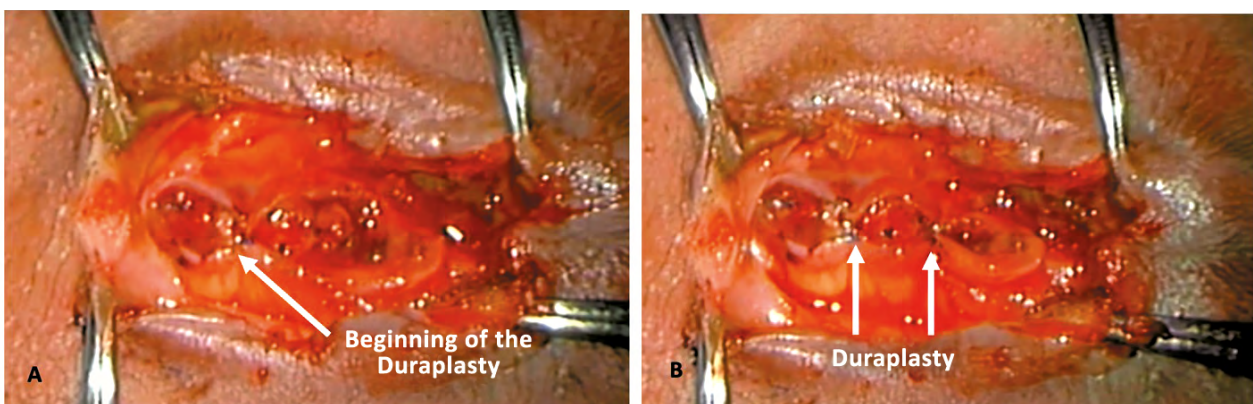


Figure 11. Reconstruction of the dural sac. A. Start with separate stitches. B. Dural reconstruction with suture in a symmetrical way to later close with continuous suture.

After reaching the dura mater a second suture plane is created using continuous and simple stitches, employing 5/0 polypropylene with a 13 mm 3/8 round atraumatic needle. The suture can commence at either the proximal or distal end. Upon completion of the dural suture, the anesthesiologist is asked to assist the patient in performing the Valsalva maneuver to visualize the outflow of cerebrospinal fluid, indicating potential incomplete closure of the spinal canal. Failure to achieve complete closure could lead to postoperative ventriculitis, a complication of MMC surgery, necessitating a second intervention to address the fistula (refer to Figure 12).

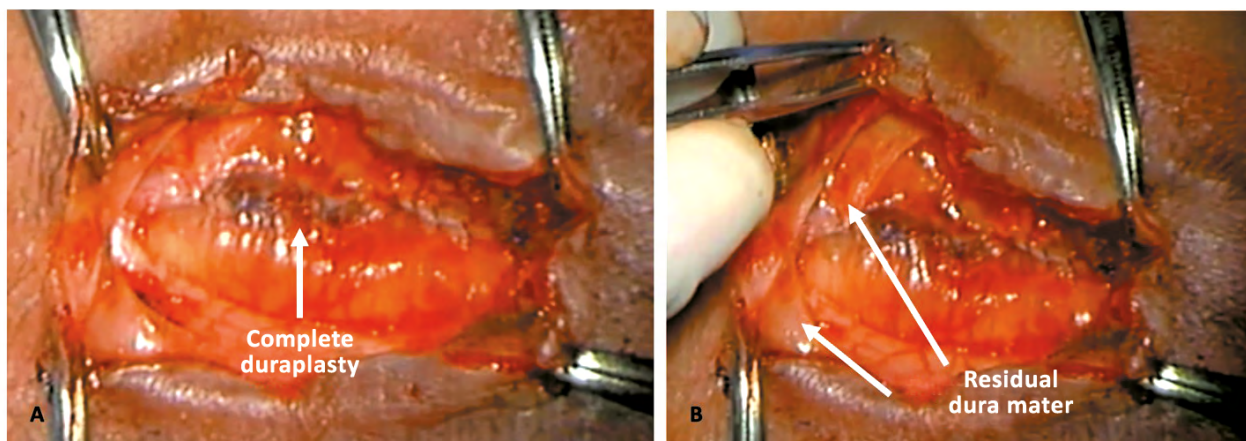


Figure 12. Reconstruction of the dural sac. A. Complete closure of the dural sac, peridural fat, and spinal dysraphism is observed. B. Residual dura mater attached to soft tissues facilitates closure, resembling an aponeurotic galea.

Aponeurotic flap reinforcement

One of the surgical techniques employed in MMC surgery to reduce the risk of cerebrospinal fluid fistula is reinforcing the paravertebral aponeurosis with a flap. Under microscopic visualization, the lumbar paravertebral fascia is identified, and using a monopolar electrode, it is carefully separated from the muscle. Dissection is conducted bilaterally, ensuring a wide reach extending at least to the midline to minimize the possibility of bleeding. The fascia is then sutured using absorbable 4/0 suture with an atraumatic needle, employing either separate stitches or a simple continuous technique, ensuring complete coverage of the dura mater (refer to Figures 13, 14, and 15).

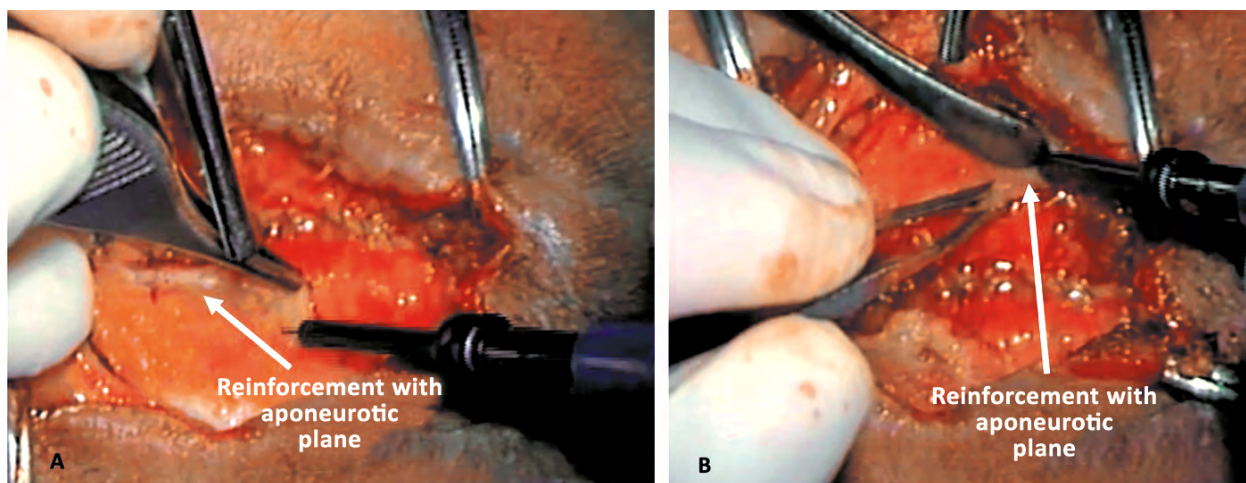


Figure 13. Reinforcement with lumbar paravertebral aponeurosis. A. Dissection of the left lumbar paravertebral aponeurosis B. Dissection of the right lumbar paravertebral aponeurosis.

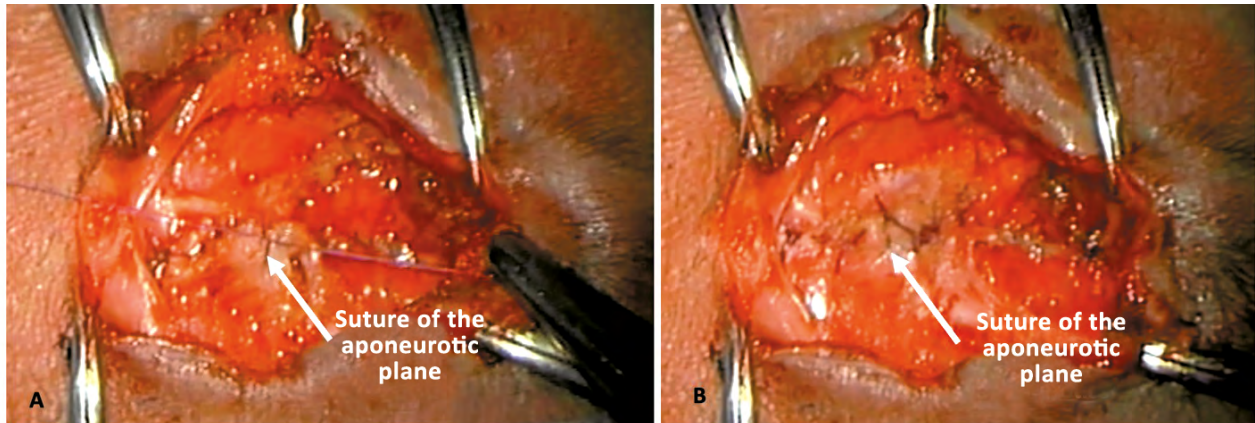


Figure 14. Suture of the paravertebral aponeuroses. A. Suture of both aponeuroses with separate stitches. B. Reinforcement with lumbar paravertebral aponeurosis concealing the dural sac.

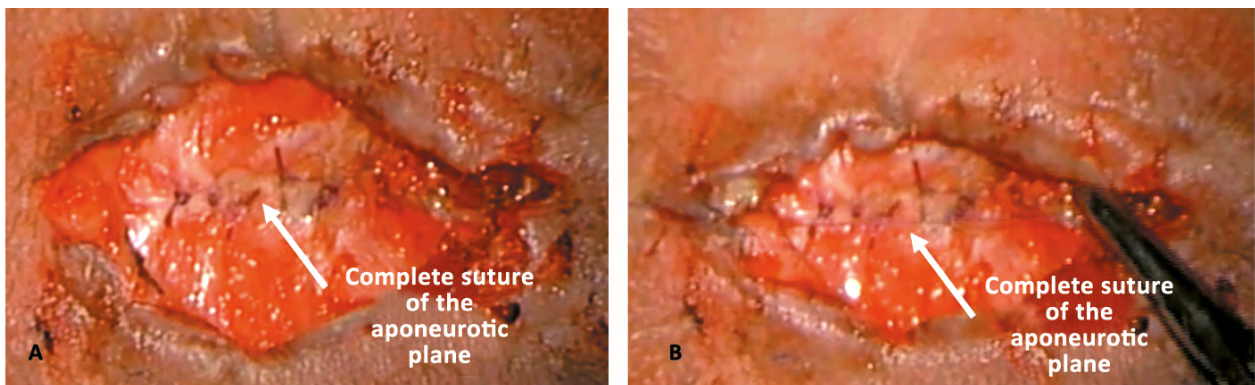


Figure 15. Suture of the paravertebral aponeuroses. A. Suture with separate stitches; neither the dural sac nor spinal canal is visualized. B. Complete closure of the aponeurotic plane.

Dissection and soft tissue approximation

As previously mentioned, during the dissection of the dura mater, a portion of it remains adhered to the subcutaneous cellular tissue, resembling the structure observed in the aponeurotic galea of the hairy skin. This portion of the dura mater facilitates tension-free closure of the skin. An absorbable 4/0 suture with a 13 mm 3/8 round atraumatic needle is used for this purpose. The suturing technique involves separate stitches and alternating placement at the distal and proximal ends to ensure the central part remains free of tension when placing the final stitch. Excessive tension in the center could lead to tissue rupture. Once this plane is addressed, dysplastic skin is carefully removed using a N° 11 scalpel, taking care not to disrupt the sutures of the deeper planes. Special attention is given to ensuring the skin edges are uniformly sectioned, enabling symmetrical suturing for optimal aesthetic results (Figure 16).

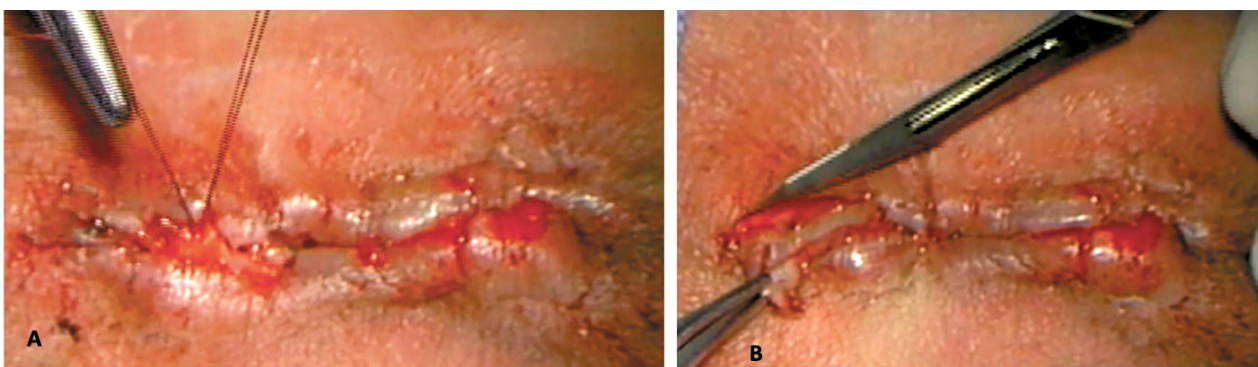


Figure 16. Soft tissue closure A. The approximation of skin edges is facilitated by the presence of residual dura mater. B. With the use of the scalpel, dysplastic skin is removed from both skin edges.

Skin closure

Once the dysplastic skin has been removed using a N° 11 scalpel, the skin is closed with 5/0 nylon with a 13 mm 3/8 sharp needle, using simple, continuous, or separate stitches. The skin closure should not be under tension to prevent operative wound dehiscence, which could lead to prolonged hospital stays or readmission to the operating room (see Figure 17).

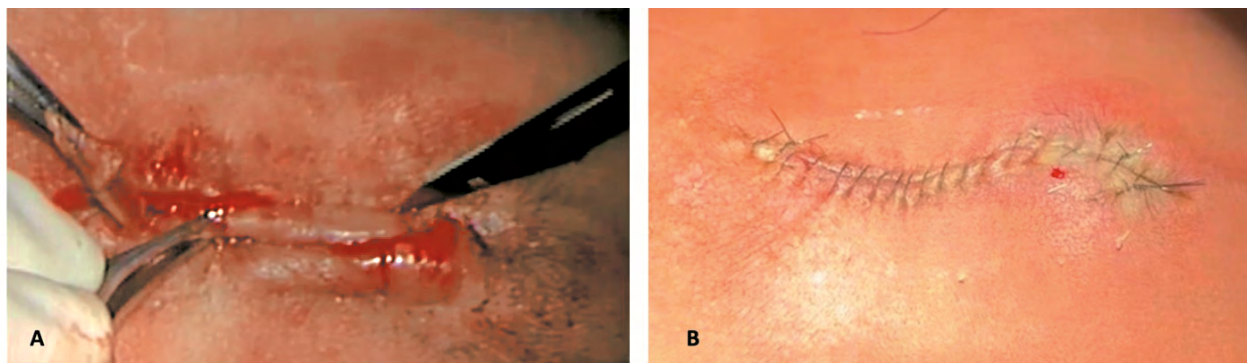


Figure 17. Soft tissue closure. A. Removal of dysplastic skin using a scalpel. B. Suture of the skin with simple continuous stitches.

DISCUSSION

Our manuscript presents a surgical technique we use in postnatal surgery for myelomeningocele (MMC), a challenging medical condition for neurosurgeons. The preoperative evaluation of the patient is critical to rule out any co-existing congenital malformations that may complicate or delay surgery. Undoubtedly, the assessment of the location and size of a defect is crucial. Ideally, surgery is scheduled within the first 48 hours of life to reduce the possibility of infection (8). It is essential to ensure proper closure of both the dura mater and the skin during surgery. To prevent cerebrospinal fluid fistula, the dura mater should be anatomically identified and dissected before closure. Closure of the skin can be complicated and requires a multidisciplinary approach. Myocutaneous flaps can be utilized for this purpose. In our experience, different incisions can lead to complications such as dehiscence and closure techniques can lead to retractile scars (9-14). The goal is to achieve a well-vascularized and tight closure, which protects the neural tissues from the environment, minimizes the risk of cerebrospinal fluid fistula, and avoids tethered medulla (15).

Surgical treatment for patients is most effective when performed within 48 to 72 hours of birth to reduce the risk of infection and further damage to the exposed neural structures (16). The detailed step-by-step surgical technique will provide the necessary concepts to decrease the morbidity and mortality of patients born with CMM. In our opinion, it is a simple surgical technique, with operative wounds proportional to the size of the CMM, and aims to be conservative to allow for possible future surgeries.

Authors' contribution

The authors confirm responsibility for the conceptualization and design, data collection, analysis, interpretation, and final manuscript preparation.

Funding

The present study was self-financed.

Ethical aspects

Not applicable.

Conflicts of interest

The authors have no conflict of interest associated with the material presented in the manuscript.

REFERENCES

1. Adzick NS. Fetal myelomeningocele: natural history, pathophysiology, and in-utero intervention. *Semin Fetal Neonatal Med.* 2010;15(1):9-14. doi: 10.1016/j.siny.2009.05.002
2. Adzick NS, Walsh DS. Myelomeningocele: prenatal diagnosis, pathophysiology and management. *Semin Pediatr Surg.* 2003;12(3):168-74. doi: 10.1016/s1055-8586(03)00029-5
3. Hassan AS, Du YL, Lee SY, Wang A, Farmer DL. Spina Bifida: A Review of the Genetics, Pathophysiology and Emerging Cellular Therapies. *J Dev Biol.* 2022;10(2):22. doi: 10.3390/jdb10020022
4. Ganesh D, Sagayaraj BM, Barua RK, Sharma N, Ranga U. Arnold Chiari malformation with spina bifida: a lost opportunity of folic Acid supplementation. *J Clin Diagn Res.* 2014;8(12):OD01-3. doi: 10.7860/JCDR/2014/11242.5335
5. Lindquist B, Jacobsson H, Strinnholm M, Peny-Dahlstrand M. A scoping review of cognition in spina bifida and its consequences for activity and participation throughout life. *Acta Paediatr.* 2022;111(9):1682-1694. doi: 10.1111/apa.16420
6. Kobraei EM, Ricci JA, Vasconez HC, Rinker BD. A comparison of techniques for myelomeningocele defect closure in the neonatal period. *Childs Nerv Syst.* 2014;30(9):1535-41. doi: 10.1007/s00381-014-2430-7
7. Juranek J, Salman MS. Anomalous development of brain structure and function in spina bifida myelomeningocele. *Dev Disabil Res Rev.* 2010;16(1):23-30. doi: 10.1002/ddrr.88
8. Kneser U, Bigdeli AK, Himmler JP, Eyüpoglu IY, Ganslandt O, Hirsch A, et al. Comparison of the Ramirez technique for the closure of large open myelomeningocele defects with alternative methods. *J Plast Reconstr Aesthet Surg.* 2015;68(12):1675-82. doi: 10.1016/j.bjps.2015.08.002
9. Emsen IM. Reconstructions With Different and New Techniques of Large and Extensive Myelomeningocele Defects. *J Craniofac Surg.* 2019;30(2):584-8. doi: 10.1097/SCS.00000000000004879
10. Highton L, Walkden J, Thorne J, Davenport PJ. Purse-string closure of large myelomeningoceles. *J Plast Reconstr Aesthet Surg.* 2011;64(11):e287-8. doi: 10.1016/j.bjps.2011.06.029
11. Emsen IM. Closure of Large Myelomeningocele Defects Using the O-S Flap Technique. *J Craniofac Surg.* 2015;26(7):2167-70. doi: 10.1097/SCS.00000000000002154
12. Cole P, Armenta A, Dauser R, Hollier L Jr. Simplifying soft tissue closure of the large meningomyelocele defect: a technical note. *J Plast Reconstr Aesthet Surg.* 2008;61(2):192-4. doi: 10.1016/j.bjps.2007.07.006
13. Shim JH, Hwang NH, Yoon ES, Dhong ES, Kim DW, Kim SD. Closure of Myelomeningocele Defects Using a Limberg Flap or Direct Repair. *Arch Plast Surg.* 2016;43(1):26-31. doi: 10.5999/aps.2016.43.1.26
14. Özçelik D, Yildiz KH, Iş M, Döşoğlu M. Soft tissue closure and plastic surgical aspects of large dorsal myelomeningocele defects (review of techniques). *Neurosurg Rev.* 2005;28(3):218-25. doi: 10.1007/s10143-004-0357-2
15. Müslüman AM, Karşıdağ S, Sucu DÖ, Akçal A, Yılmaz A, Sirinoğlu D, et al. Clinical outcomes of myelomeningocele defect closure over 10 years. *J Clin Neurosci.* 2012;19(7):984-90. doi: 10.1016/j.jocn.2011.09.026
16. Di Rocco C, Trevisi G, Massimi L. Myelomeningocele: an overview. *World Neurosurg.* 2014;81(2):294-5. doi: 10.1016/j.wneu.2013.02.042