

CASE REPORT

Planning and 3D printing in facial reconstruction due to a highly complex multiple fracture in a pediatric patient: a case report

Alfredo Broggi-Angulo¹, Edgar Salas-Moscoso¹, Jesús Abel Macarlupú-Atarama¹, Alfredo Giovanni Broggi-Ruiz²

¹Unidad de Atención Integral Especializada. Instituto Nacional de Salud del Niño San Borja, Lima, Perú

²Universidad San Martín de Porres, Lima, Perú

ABSTRACT

We present a clinical case of a 16-year-old patient with multiple facial fractures as a result of a third-party physical attack, for which he underwent facial reconstruction after planning and 3D printing. This case report aims to highlight the importance of using technologies such as 3D printing to reconstruct the face following panfacial trauma in a pediatric patient. 3D printing facilitates the reproduction of anatomically sized custom models designed in software from images of a tomographic study, as recent studies reinforce the benefits of using 3D printing for good preoperative planning and achieving the patient's postoperative goals.

Keywords: Accidents, Traffic; Fractures, Bone, Printing, Three-Dimensional (Source: MeSH)

Cite as:

Broggi-Angulo A, Salas-Moscoso E, Macarlupú-Atarama JA, Broggi-Ruiz AG. Planning and 3D printing in facial reconstruction due to a highly complex multiple fracture in a pediatric patient: a case report. *Investig Innov Clin Quir Pediatr.* 2023;1(2):63-8. doi:10.59594/iicqp.2023.v1n2.67

Corresponding author:

Alfredo Broggi Angulo
Address: Parque Colmenares 248
3er piso, Pueblo Libre, Lima, Perú
Telephone: +51999920224
E-mail: alfredbroggi98@yahoo.es


Planificación e impresión en 3D en reconstrucción facial por fractura múltiple de alta complejidad en un paciente pediátrico: a propósito, un caso


RESUMEN


Presentamos el caso clínico de un paciente de 16 años con múltiples fracturas en el macizo facial secundaria a una agresión física por terceros, por lo que, se le realizó una reconstrucción facial previa planificación e impresión en 3D. El objetivo de este reporte de caso, es resaltar la importancia del uso de tecnologías como la impresión en 3D en la reconstrucción de cara por un trauma panfacial en un paciente pediátrico. La impresión en 3D facilita la reproducción de modelos personalizados en tamaño anatómico diseñados en un software desde imágenes de un estudio tomográfico, pues los últimos estudios fortalecen el beneficio que trae consigo el uso de la impresión en 3D para un buen plan de trabajo preoperatorio y alcanzar los objetivos post operatorios en el paciente.


Palabras clave: Accidentes de Tránsito; Fracturas Óseas; Impresión Tridimensional (Fuente: DeCS)

ORCID iDs

Alfredo Broggi-Angulo
 <https://orcid.org/0009-0003-9262-3597>

Edgar Salas-Moscoso
 <https://orcid.org/0000-0002-5225-2483>

Jesús Abel Macarlupú-Atarama
 <https://orcid.org/0009-0004-2627-3944>

Alfredo Giovanni Broggi Ruiz
 <https://orcid.org/0000-0002-2752-0343>

Received : 21/09/2023

Accepted : 15/12/2023

Published : 29/12/2023



This publication is licensed under a Creative Commons Attribution 4.0 International License.

Copyright © 2023, The authors

INTRODUCTION

Injuries of traumatic origin due to falls or traffic accidents are the most frequent cause of highly complex maxillofacial trauma in the pediatric population (15%) (1-3), injuring bones, dentoalveolar, vascular, and nervous structures (4). In addition, they can cause functional and esthetic alterations that could lead to morbidity and even mortality of the patient. Pediatric patients who suffer a maxillofacial trauma should undergo an exhaustive study, from a thorough physical examination to a CT scan with 3D reconstruction, and even virtual surgical planning and 3D printing in cases of complex facial fractures. After having performed the pre-surgical planning (5), the reconstruction of the facial mass is performed, being this a surgical act that involves fracture reduction followed by osteosynthesis with titanium plates, meshes, and screws that have been previously molded in a 3D printed model.

The development of 3D technology has allowed the creation of models that replicate the anatomy at an accurate scale with maxillofacial trauma defects based on tomography images that are processed in software. These resources have contributed to preoperative planning and surgeon training and reduced anesthetic and surgical time with accurate results (6,7).

The bending of osteosynthesis material such as titanium plates and meshes is done manually, and performing this process during surgery is time-consuming (8) and presents a significant degree of difficulty, sometimes failing to achieve the exact desired molding. Therefore, the use of a 3D printed anatomical model would help to improve the precision (9) of the plates molded to the fracture traces, avoiding, during surgery, the task of molding the plates in complex fractures, which would reduce the surgical time with less manipulation of the soft tissues. In addition, it reduces the risk of surgical wound infection, reducing hospital stay and morbidity (10,11), obtaining optimal and predictable results of facial reconstruction, benefits that were reflected in the patient of the presented report.

The usefulness of 3D printing has expanded in different medical specialties, becoming a potential tool for the diagnosis and treatment planning of pathologies involving bone structures, whether traumatic, tumoral (12), or congenital (13). In this sense, the surgeon's involvement with these cutting-edge technologies is emphasized; hence, this report aims to highlight the importance of the usefulness of 3D printing in facial reconstruction due to a highly complex multiple fracture in a pediatric patient.

CLINICAL CASE

A male patient, 16 years old, with no previous history of importance, from Chimbote - Peru, who suffered aggression by third parties and presented a highly complex panfacial traumatism, for which he was referred to a high complexity specialized hospital in Lima and was admitted to the intensive care unit for ventilatory and hemodynamic support management. On physical examination, the patient was awake, obeyed orders, was intubated, and had a lacerating wound in the frontal and nasal region and pan-facial edema. There were palpable staggered areas in the 3 facial thirds, bilateral palpebral ecchymosis, and epistaxis. In addition, the patient showed preserved vision and ocular movements.

Advanced imaging studies were performed for his evaluation, including a contrast-enhanced multislice spiral CT scan and a 3D reconstruction of the facial massif (Figure 1A). These examinations revealed the presence of a hematoma in the frontal region, for which the neurosurgical team recommended keeping the patient under observation. In addition, imaging studies showed multiple traces of fractures in various structures of the facial massif, affecting the frontal, zygomatic, maxillary, nasal, and mandibular bones. Due to the complexity and extension of these fractures, the case was evaluated by specialists in Head, Neck, and Maxillofacial Surgery.

Due to these findings, the surgical team decided to perform the planning and 3D printing of a personalized model (Figure 1B) for facial reconstruction due to a highly complex multiple fracture. To manage the airway, occlusion, and access to all fractures, endotracheal intubation was performed through the submental route and use of the printed model during surgery (Figure 1C).

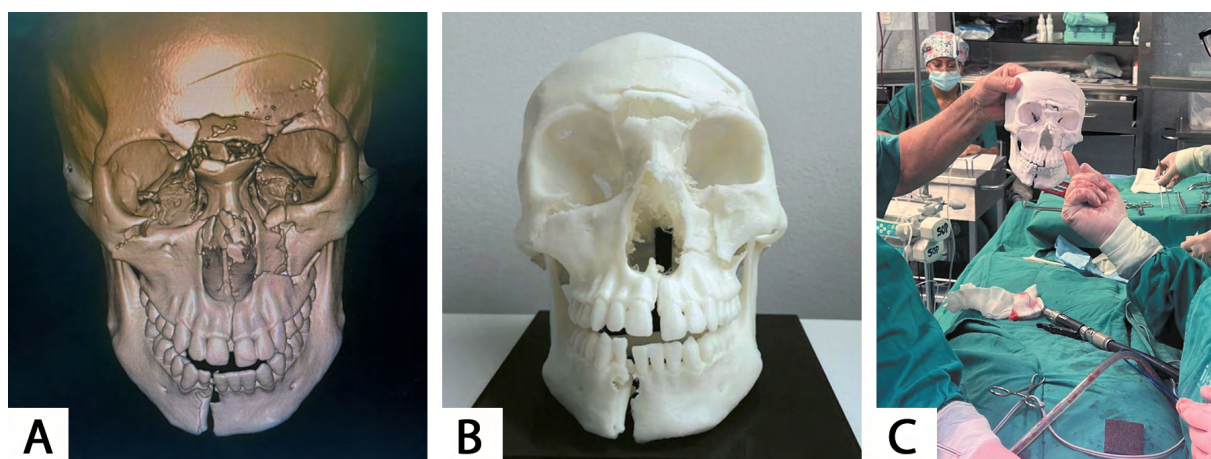


Figure 1. A. 3D reconstruction of facial mass tomography. B. Custom 3D printed model. C. Utility of 3D printing during surgery.

The operation, which lasted approximately 2 hours, began with a frontal wound approach (Figure 2D) to treat a comminuted and complex fracture in the nasofrontal region. A system 1.0 titanium pre-molded mesh tailored to the defect was used (Figure 2E). Also, bilateral Caldwell-Luc and inferior vestibule approaches were used to reduce and fix the bilateral maxilla (Figure 3F-H) and mandible (Figure 4). For reconstruction, pre-molded plates and 1.5 and 2.0 mm system titanium screws were used and placed in the abutments and buttresses [1] affected by the fractures with the objective of function and symmetry of the facial massif.

The patient was discharged after 5 days, with postoperative follow-up including a multislice spiral CT scan of the facial massif (Figure 5). Currently, the patient has reintegrated into his daily activities without complications. Three months after surgery, a 3D printing of personalized models showing before and after surgery was performed, highlighting the successful and effective results of the facial reconstruction (Figure 6).

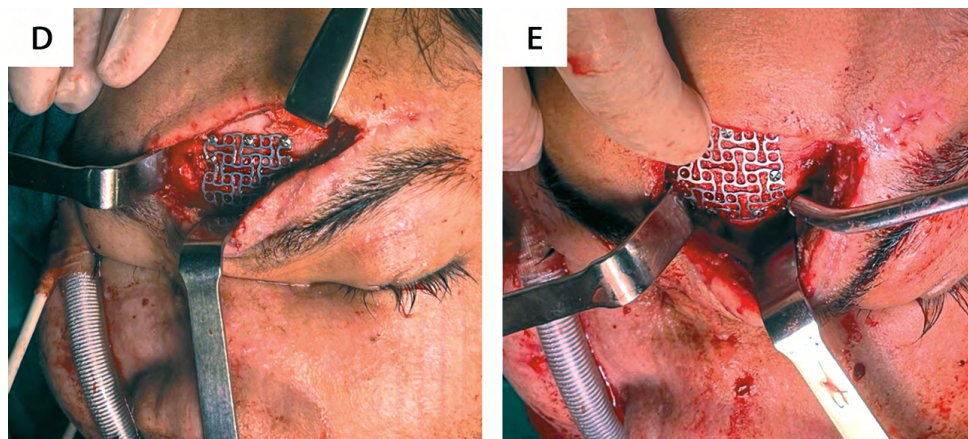


Figure 2. Upper facial third D. Frontal wound approach. E. Placement of mesh and titanium screws in multiple fractures of the nasolabial frontal region.

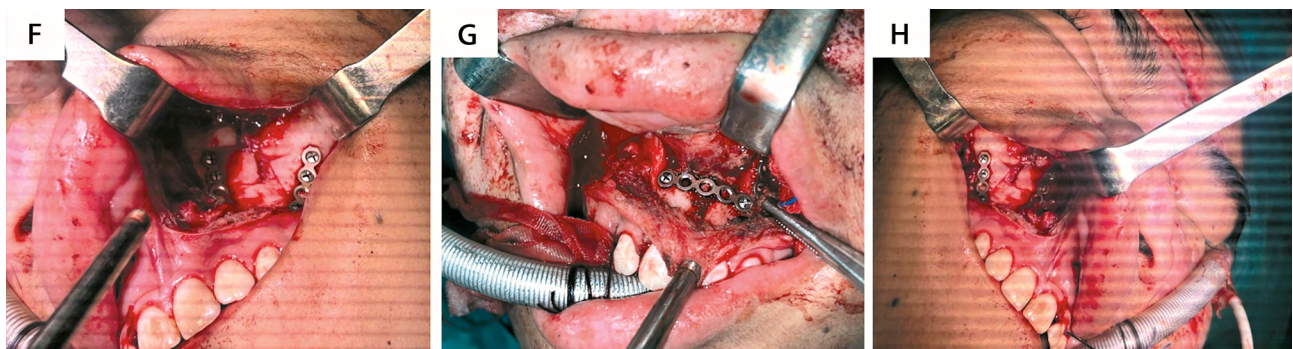


Figure 3. Middle facial third F. Placement of the plate and titanium screw system 1.5 in left external pillar fracture. G. Placement of the plate and titanium screw system 1.5 in maxillary symphysis fracture. H. Placement of the plate and titanium screw system 1.5 in right external pillar fracture.

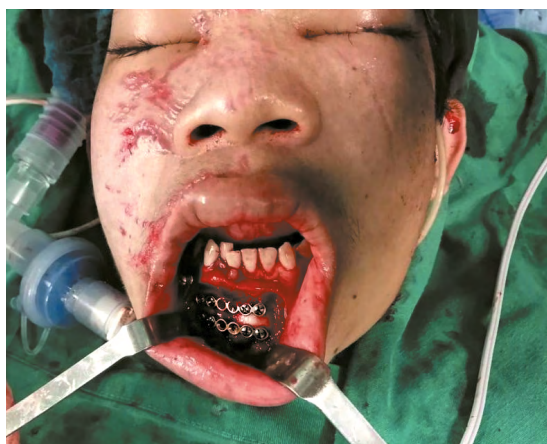

Figure 4. Lower facial third: titanium plates and screws system 2.0 in multiple parasymphyseal fractures of the lower maxillary bone.

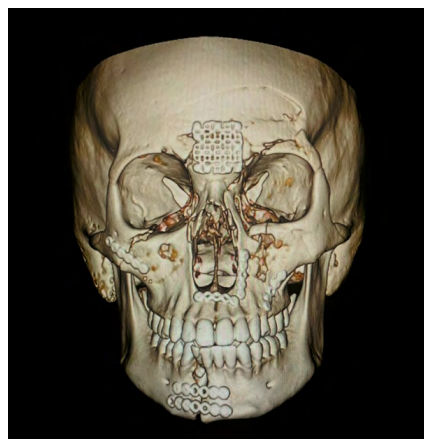

Figure 5. Postoperative control of 3D reconstruction of facial mass tomography.

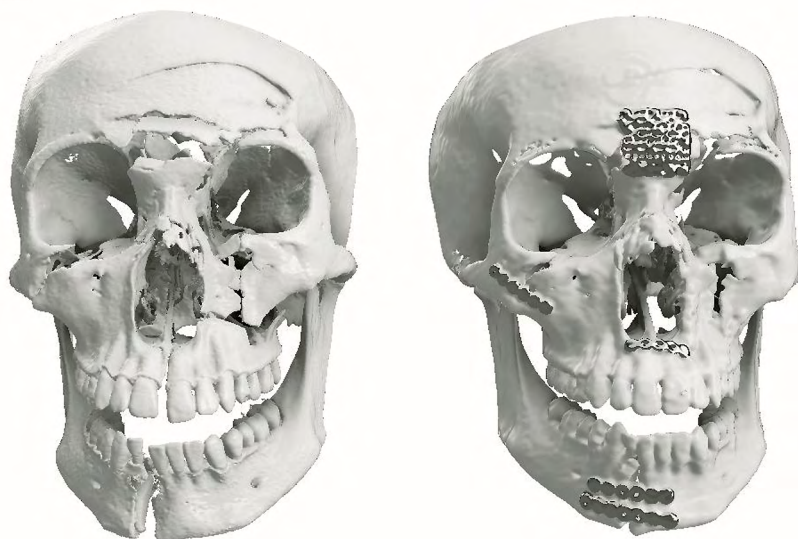


Figure 6. Comparison of the customized 3D printed models before and after surgery.

DISCUSSION

Facial traumatism is more frequent in the adolescent group, as mentioned in the study of Gordillo *et al.* (14), as opposed to the pediatric population, which is smaller but with a higher frequency of being related to cranial trauma in children. The most frequent causes of these complex maxillofacial traumatisms are falls or traffic accidents (3), unlike our patient, who suffered aggression by third parties.

These complex facial traumas require joint and specialized management to achieve the reconstruction objectives. The development of new techniques during the last years has allowed us to improve considerably and obtain better results, decreasing the surgical time; besides the reduction of morbidity related to infectious risk with a decrease in hospital stay, reasons for cost-benefit were reflected in our patient (6,7).

The introduction of 3D printing has marked a milestone in the development of surgery that has transcended the diagnosis and treatment of maxillofacial reconstructions, managing to recover the functionality and harmonization of the face in pathologies such as facial trauma, tumors, or maxillofacial dysostosis that require orthognathic surgery (15).

The use of 3D printing related to reconstructive surgery for fractures, malformations, and others has been reported in the literature (16). However, due to the lack of controlled studies, the contribution to surgery for post-traumatic injuries is not clear (17), so it is essential to evaluate the use of this visual and tactile tool in pathologies involving the facial massif. Using these new tools allows planning and interacting with a model that reflects the anatomy and defects caused by trauma (18). In addition, in this case, the molding of the osteosynthesis material, such as titanium plates and meshes, was done manually, making use of the 3D printed model facilitating the precision of the molded plates to the fracture traces, avoiding during surgery the task of molding the plates in unstable fractures, thus decreasing the surgical time and obtaining optimal results of facial reconstruction, as mentioned by Kuehle et al.

According to Mantrana et al. (10), using 3D models in pre-surgical planning reduced anesthetic-surgical time by 20%, obtaining the desired result and highlighting the advantages of using this tool for planning and as a guide during surgery. In previous studies, the estimated time was from 30 minutes to 2 hours for reconstructions with plates (7) previously molded to the surgery, a time similar to the case of our patient. Likewise, other authors mention that they decreased surgical time using models used in the preoperative planning of mandibular reconstructions (20-22).

3D printing is a safe and precise tool that is very useful in the preoperative planning of maxillofacial reconstruction for different causes, so the surgeon needs to become familiar with the applications and evolution of 3D printing technologies (23). On the other hand, 3D printing tools are available in the market that provide the surgeon with customized models for exceptional cases (23), becoming the most common method in craniofacial surgery planning (24).

Conclusion

This study highlights the importance and efficacy of 3D printing in the facial reconstruction of complex maxillofacial trauma in pediatric patients. The case of a 16-year-old assault victim demonstrates how advanced technologies, such as 3D printing of customized models, facilitate surgical planning and execution, significantly reducing surgical time and improving aesthetic and functional outcomes. This innovative approach, which combines advanced surgery with state-of-the-art technology, would improve surgical outcomes and highlight the relevance of integrating new technologies into surgical practice, especially in highly complex cases such as maxillofacial reconstructions.

Authorship contributions: ABA contributed to the formulation of the original idea. JAMA reviewed the clinical history as well as the images. All authors drafted, reviewed, and approved the final version of the manuscript.

Financing: Self-financed

Conflicts of interest: The authors declare no conflicts of interest.

REFERENCES

- Eggensperger Wymann NM, Hölzle A, Zachariou Z, Iizuka T. Pediatric craniofacial trauma. *J Oral Maxillofac Surg.* 2008;66(1):58-64. doi: 10.1016/j.joms.2007.04
- Haug RH, Foss J. Maxillofacial injuries in the pediatric patient. *Oral Surg Oral Med Oral Pathol Oral Radiol Endod.* 2000;90(2):126-34. doi: 10.1067/moe.2000.107974
- Afroz PN, Bykowski MR, James IB, Daniali LN, Clavijo Alvarez JA. The Epidemiology of Mandibular Fractures in the United States, Part 1: A Review of 13,142 Cases from the US National Trauma Data Bank. *J Oral Maxillofac Surg.* 2015;73(12):2361-6. doi: 10.1016/j.joms.2015.04.032
- Kakarala K, Shnayder Y, Tsue TT, Girod DA. Mandibular reconstruction. *Oral Oncol.* 2018;77:111-7. doi: 10.1016/j.oraloncology.2017.12.020
- Telich-Tarriba JE, Ramírez-Sosa LE, Palafox D, Ortega-Hernandez E, Rendón-Medina MA. Aplicaciones de la impresión 3D en cirugía plástica reconstructiva. *Rev Fac Med.* 2020;68(4):603-7. doi: 10.15446/revfacmed.v68n4.77862
- Escalona-Contreras N, Merino-Kutscher P, Cartes-Velásquez R. Uso de técnicas de impresión 3D en la reconstrucción mandibular. Una revisión breve. *CES Odonto.* 2021;34(2):159-72. doi: 10.21615/cesodon.5939
- Dupret-Bories A, Vergez S, Meresse T, Brouillet F, Bertrand G. Contribution of 3D printing to mandibular reconstruction after cancer. *Eur Ann Otorhinolaryngol Head Neck Dis.* 2018;135(2):133-6. doi: 10.1016/j.anorl.2017.09.007
- Martelli N, Serrano C, van den Brink H, Pineau J, Prognon P, Borget I, et al. Advantages and disadvantages of 3-dimensional printing in surgery: A systematic review. *Surgery.* 2016;159(6):1485-500. doi: 10.1016/j.surg.2015.12.017
- Naros A, Weise H, Tilsen F, Hoefert S, Naros G, Krimmel M, et al. Three-dimensional accuracy of mandibular reconstruction by patient-specific pre-bent reconstruction plates using an "in-house" 3D-printer. *J Craniofac Surg.* 2018 Sep;46(9):1645-51. doi: 10.1016/j.jcms.2018.05.047
- Mantrana G, Jacobo O, Hartwig D, Giachero V. Three-Dimensional printing models in the preoperative planning and academic education of mandible fractures. *Cir Plast Iberolatinoam.* 2018;44(2):193-201. doi: 10.4321/s0376-78922018000200010.
- Zhang Q, Wu W, Qian C, Xiao W, Zhu H, Guo J, et al. Advanced biomaterials for repairing and reconstruction of mandibular defects. *Mater Sci Eng C Mater Biol Appl.* 2019;103:109858. doi: 10.1016/j.msec.2019.109858
- Lombard T, Systemans S, Goffinet M, Gilon Y. La médecine du futur. Planificación 3D : de la résection carcinologique à la reconstrucción maxilofacial. *Rev Med Lieja.* 2022;77(3):187-91.
- Hidalgo HM, Romo GW, Estolano RT. Stereolithography: a method for planning the surgical correction of the hypertelorism. *J Craniofac Surg.* 2009;20(5):1473-7. doi: 10.1097/SCS.0b013e3181b09a70
- Gordillo Yépez FD, Nascimento Mileto T, Taparello C, De Conto E, Engelmann JL, Pinheiro Siqueira S. Traumatismo facial en niños y adolescentes: un análisis de 10 años en un hospital de la región sur de Brasil. *Odontoestomatol.* 2020;22(5):30-7. doi: 10.22592/ode2020n35a5

15. Zoabi A, Redenski I, Oren D, Kasem A, Zigron A, Daoud S, et al. 3D Printing and Virtual Surgical Planning in Oral and Maxillofacial Surgery. *J Clin Med.* 2022;11(9):2385. doi: 10.3390/jcm11092385
16. Pallo Sarabia MS, González Cardona Y. Abordaje desde el proceso docente en Odontología a la tecnología 3d aplicada en reconstrucciones bucomaxilofaciales. *Conrado.* 2023;19(93):167-76.
17. Murray-Douglass A, Snoswell C, Winter C, Harris R. Three-dimensional (3D) printing for post-traumatic orbital reconstruction, a systematic review and meta-analysis. *Br J Oral Maxillofac Surg.* 2022;60(9):1176-1183. doi: 10.1016/j.bjoms.2022.07.001
18. Bizzotto N, Sandri A, Regis D, Romani D, Tami I, Magnan B. Three-Dimensional Printing of Bone Fractures: A New Tangible Realistic Way for Preoperative Planning and Education. *Surg Innov.* 2015;22(5):548-51. doi: 10.1177/1553350614547773
19. Kuehle R, Kuebler M, Fuchs J, Weichel F, Moratin J, Freier K, et al. The value of prebent reconstruction plates and in-house 3D printing. *J Stomatol Oral Maxillofac Surg.* 2023;124(1S):101381. doi: 10.1016/j.jormas.2023
20. Chan HH, Siewerdsen JH, Vescan A, Daly MJ, Prisman E, Irish JC. 3D Rapid Prototyping for Otolaryngology-Head and Neck Surgery: Applications in Image-Guidance, Surgical Simulation and Patient-Specific Modeling. *PLoS One.* 2015;10(9):e0136370. doi: 10.1371/journal.pone.0136370
21. Lethaus B, Poort L, Böckmann R, Smeets R, Tolba R, Kessler P. Additive manufacturing for microvascular reconstruction of the mandible in 20 patients. *J Craniomaxillofac Surg.* 2012;40(1):43-6. doi: 10.1016/j.jcms.2011.01.007
22. Hanasono MM, Jacob RF, Bidaut L, Robb GL, Skoracki RJ. Midfacial reconstruction using virtual planning, rapid prototype modeling, and stereotactic navigation. *Plast Reconstr Surg.* 2010;126(6):2002-6. doi: 10.1097/PRS.0b013e3181f447e1
23. Hatz CR, Msallem B, Aghlmandi S, Brantner P, Thieringer FM. Can an entry-level 3D printer create high-quality anatomical models? Accuracy assessment of mandibular models printed by a desktop 3D printer and a professional device. *Int J Oral Maxillofac Surg.* 2020;49(1):143-8. doi: 10.1016/j.ijom.2019.03.962
24. Ghai S, Sharma Y, Jain N, Satpathy M, Pillai AK. Use of 3-D printing technologies in craniomaxillofacial surgery: a review. *Oral Maxillofac Surg.* 2018;22(3):249-59. doi: 10.1007/s10006-018-0704-z