

REVIEW

Diagnostic imaging in congenital diaphragmatic hernia, more than just a diaphragmatic defect: a narrative review

Florencia De Barbieri Magnone¹, Paulina Esparza Olave¹, Luis Ziehe Moreira¹

¹ Departamento de Radiología del Hospital Clínico de la Pontificia Universidad Católica de Chile, Santiago, Chile

ABSTRACT

Congenital diaphragmatic hernia is a relatively common major malformation with a life-threatening prognosis. This condition involves an abnormal development of the diaphragm, lungs, and particularly the blood vessels and other related structures. Images of these structures are essential for diagnosis, pre- and postoperative assessment, and serial monitoring. In the prenatal period, ultrasound plays a fundamental role in early diagnosis; ultrasound and magnetic resonance allow evaluation of the degree of lung hypoplasia and the presence of associated anomalies to predict survival and the possible need for more complex strategies such as extracorporeal membrane oxygenation (ECMO) in the perinatal period. In the postnatal period, portable radiography and ultrasound are essential in the serial assessment of children, whether they receive supportive therapies such as invasive mechanical ventilation, ECMO, or surgery. Knowledge of the pathophysiology and radiological manifestations of each of these phases is essential to allow appropriate assessment, optimize treatment, and ultimately improve the survival of these children.

Keywords: Hernias, Diaphragmatic, Congenital; Prognosis; Diaphragm (Source: MeSH)

Diagnóstico por imágenes en hernia diafragmática congénita, más que solo un defecto diafragmático: una revisión narrativa

RESUMEN

La hernia diafragmática congénita es una malformación mayor relativamente frecuente con un pronóstico potencialmente mortal. Incluye no sólo la alteración del desarrollo del diafragma, sino también de los pulmones, en especial de su vasculatura y de otras estructuras relacionadas. Las imágenes son cruciales en el diagnóstico, evaluación pre y post quirúrgica y control seriado. En la etapa prenatal la ecografía tiene un rol fundamental en el diagnóstico precoz, la resonancia magnética fetal permiten evaluar el grado de hipoplasia pulmonar y la presencia de anomalías asociadas para predecir la sobrevida y el eventual requerimiento de estrategias de mayor complejidad en el periodo perinatal como la oxigenación por membrana extracorpórea (ECMO). En la etapa postnatal la radiografía portátil y la ecografía son fundamentales en la evaluación seriada de los niños, ya sean sometido a terapias de soporte como ventilación mecánica invasiva, ECMO o a cirugía. El conocer la fisiopatología y las manifestaciones radiológicas de cada una de estas fases es fundamental para permitir una adecuada evaluación, optimizar el tratamiento y finalmente mejorar la sobrevida de estos niños.

Palabras clave: Hernias Diafragmáticas Congénitas; Pronóstico; Diafragma (Source: DeCs)

INTRODUCTION

Congenital diaphragmatic hernias (CDH) represent a major congenital malformation that occurs relatively frequently, affecting approximately one in every 2,500 to 4,000 newborns (1,2). These hernias are caused by a defect in the development of the diaphragm, which allows the ascent of intra-abdominal structures into the thoracic cavity. This leads to various alterations in lung development, including secondary pulmonary hypoplasia and pulmonary hypertension. Approximately 40-50% of CDH cases are associated with other congenital anomalies, with congenital heart disease (23%) and chromosomopathies (15%) being the most common (3). In addition, this condition is associated with high morbidity and mortality, reaching rates of up to 37% in the most specialized medical centers (4).


Cite as:

De Barbieri Magnone F, Esparza Olave P, Ziehe Moreira L. Diagnostic imaging in congenital diaphragmatic hernia, more than just a diaphragmatic defect: a narrative review. *Investig Innov Clin Quir Pediatr.* 2023;1(2):30-8. doi:10.59594/iicqp.2023.v1n2.62

Corresponding author:

Florencia De Barbieri Magnone
Address: Marcoleta 377, 5to piso, 8330024 Santiago, Región Metropolitana, Chile
Telephone: +56986690736
E-mail: florenciadebarbieri@gmail.com

ORCID iDs

Florencia De Barbieri Magnone
 <https://orcid.org/0000-0002-9894-2615>
Paulina Esparza Olave
 <https://orcid.org/0009-0005-7847-9028>
Luis Ziehe Moreira
 <https://orcid.org/0009-0005-0268-4754>

Received : 19/09/2023

Accepted : 09/11/2023

Published : 29/12/2023



This publication is licensed under a Creative Commons Attribution 4.0 International License.

Copyright © 2023, The authors

The prognosis of CDH has improved in recent years owing to various contributing factors: early diagnosis, birth in highly complex medical centers, the adoption of more aggressive therapies such as ex utero intrapartum treatment (EXIT) or extracorporeal membrane oxygenation (ECMO), and in some cases, intrauterine treatment. Radiologists play a crucial role in this context, their familiarity with prenatal findings being essential, particularly in the evaluation of fetal MRI. Equally important is their role in postnatal diagnosis, which involves recognizing common findings, identifying possible complications of this pathology, and performing effective short- and medium-term follow-up.

EMBRYOLOGY AND CLASSIFICATION

The diaphragm develops from four main elements: the transverse septum, the pleuroperitoneal canals, the mesoesophagus, and the abdominal musculature (5) (see Figure 1). The absence or abnormal development of any of these structures can give rise to different types of diaphragmatic hernias.

Intrapleural hernias, which represent up to 80% of all diaphragmatic hernias (HD) (6), originate from defects in the development of the pleuroperitoneal canals and their union with the muscles of the thoracic wall, fundamental structures in the formation of most of the muscular diaphragm. These hernias can be posteromedial or posterolateral (also known as Bochdalek hernias). Bochdalek hernias are almost always associated with pulmonary hypoplasia due to the ascension of intestinal loops and solid organs into the thoracic cavity. They are more frequent on the left side (85 to 90%), followed by hernias on the right side (10 to 15%) and bilateral hernias (2%). Approximately 20% of these hernias present a hernia sac (7).

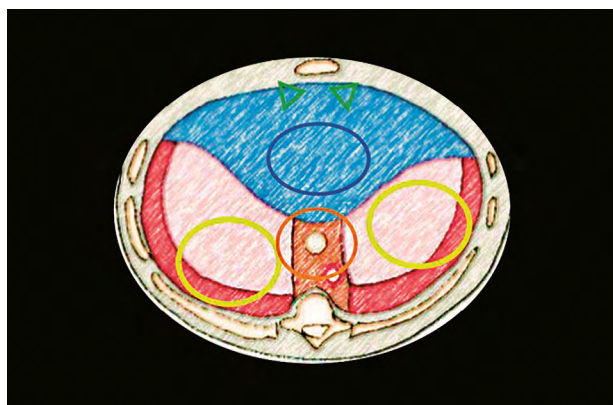


Figure 1. Diaphragmatic hernia in Cross-sectional imaging.

In contrast, failure in the development of the remaining segments of the diaphragm leads to extrapleural hernias, which do not usually cause pulmonary hypoplasia. When the transverse septum is affected, anterior hernias are formed, which can be large, allowing the ascent of part of the liver, and Morgagni hernias, characterized by small anterior paramedian hernias. Defects in the development of the mesoesophagus give rise to posterior hernias of the esophageal hiatus (hiatal hernias) and of the hiatus of the inferior vena cava.

IMAGING METHODS

Prenatal study

Currently, prenatal ultrasound has significantly improved prenatal care, allowing antenatal diagnosis of more than 60% of children with HD (8). Although hernias may be evident in the first trimester, it is more common to identify them during the second trimester through morphologic ultrasonography (9). Early diagnosis is generally associated with a more severe prognosis. On ultrasound, cardiac displacement and gastric and bowel loop enlargement are commonly seen. Evaluation of hepatic enlargement can present challenges, as can detecting right-sided HD.

On the other hand, fetal Magnetic Resonance Imaging (fMRI) has emerged as an excellent complementary tool to evaluate CDH since it allows the evaluation of associated anomalies and, given its great capacity to differentiate tissues, it allows a more accurate evaluation of lung volumes and hepatic ascites. In addition, in cases where sonographic evaluation is limited by oligohydramnios or maternal obesity, it allows an adequate characterization of fetal pathologies (see Figure 2).

Prenatal Imaging Prognostic Factors in CDH

Pulmonary hypoplasia: Pulmonary hypoplasia is identified as the factor most significantly associated with morbidity and mortality in individuals with CDH, although altered pulmonary function does not always directly correlate with the degree of hypoplasia (1,2,3,10). Prenatal determination of lung volumes is essential for decisions regarding prenatal intervention and for the possible referral of the mother to a center specialized in high-complexity neonatal management.

The lung-to-head ratio, known as LHR, is commonly used to evaluate lung volume. This method involves ultrasound measurement of the maximum volume of the lung contralateral to the herniation, taken in the transverse plane at the level of the four cardiac

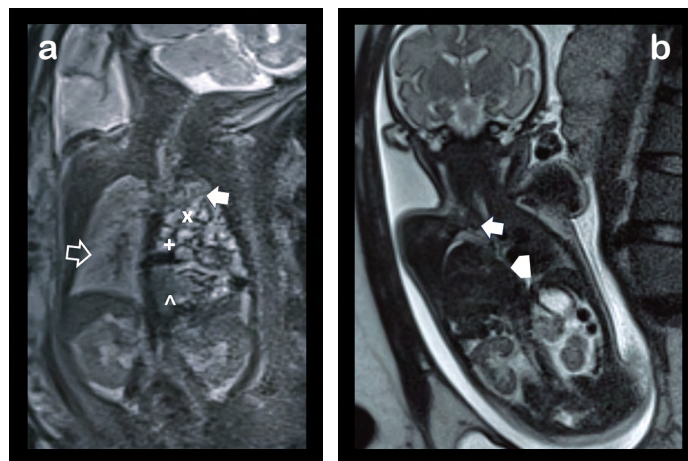


Figure 2. Fetal MR images of Diaphragmatic Hernias.

chambers and divided by the diameter of the cranial circumference. It has been estimated that an LHR of less than 1 indicates poor prognosis, a value between 1 and 1.4 suggests the need for ECMO, and a value greater than 1.4 is associated with a survival rate close to 100%. These values can be compared with average lung volumes for gestational age, thus providing the estimated versus expected (O/E) value, where a value of less than 25% indicates severe hypoplasia (11, 12). These measurements can be obtained using various online calculators (13).

Fetal magnetic resonance imaging (fMRI) is another valuable tool in this process, as it allows a more accurate measurement of lung volumes. Measurements are performed manually on axial or coronal slices covering the entire fetal thorax, without motion artifacts, and using SSFSE T2 sequences with a slice thickness of 3 to 4 mm. Using PACS tools, the lung contours are marked excluding mediastinal and bony structures, and the volume is calculated by summing the areas obtained in each slice and multiplying by the slice thickness. The volumes calculated in two planes are averaged to obtain the estimated lung volume (14) (see Figure 3). This volume is correlated with the expected lung volume for gestational age, using Rypens' formula (15) or Meyers' tables (16). Values below 25% indicate significant hypoplasia and high mortality, while values above 35%, in combination with hepatic ascites, are associated with the need for ECMO. For fetuses weighing less than the 5th percentile or greater than the 95th percentile, the percentage predicted lung volume (PPLV) is evaluated by subtracting the volume of the mediastinal structures from the total thoracic volume and comparing it with the actual lung volume. A PPLV of less than 15% is associated with 40% survival, while a value of more than 20% correlates with 100% survival. Attempts have been made to identify other imaging markers of lung maturation, such as signal intensity of the lungs compared to liver or muscle (17) and ADC values (18), but the results have been inconclusive.

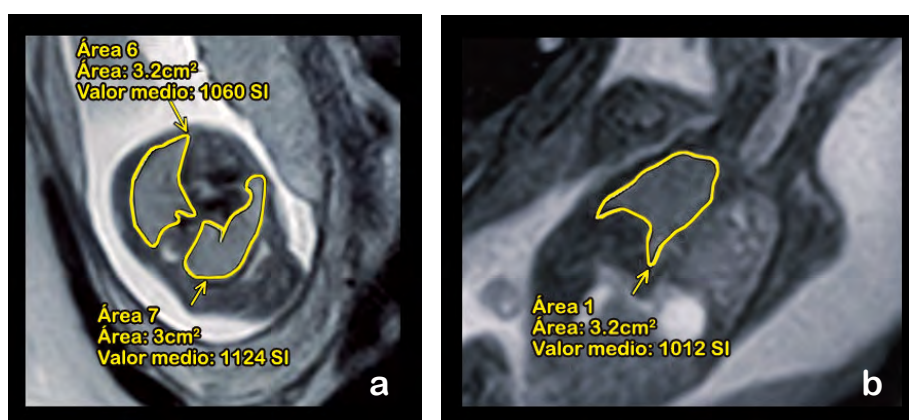


Figure 3. Measurement of Pulmonary Area in Fetal MRI.

Hepatic ascent: Ascent of the liver into the thoracic cavity in the left CDH represents an important prognostic indicator. In these cases, the absence of hepatic herniation is associated with a survival rate close to 80%. Generally, the left hepatic lobe ascends, located anteriorly and adjacent to the heart, displacing the stomach posteriorly. MRI allows a better anatomical appreciation of the hepatic ascent using T2 and T1 sequences (in which the liver is seen more hyperintense than the other structures) and also to evaluate the percentage of the herniated organ with a technique similar to that described for evaluating pulmonary volumes. Values higher than 20% are associated with a worse prognosis, with a survival of 42% (19) (see Figure 4).

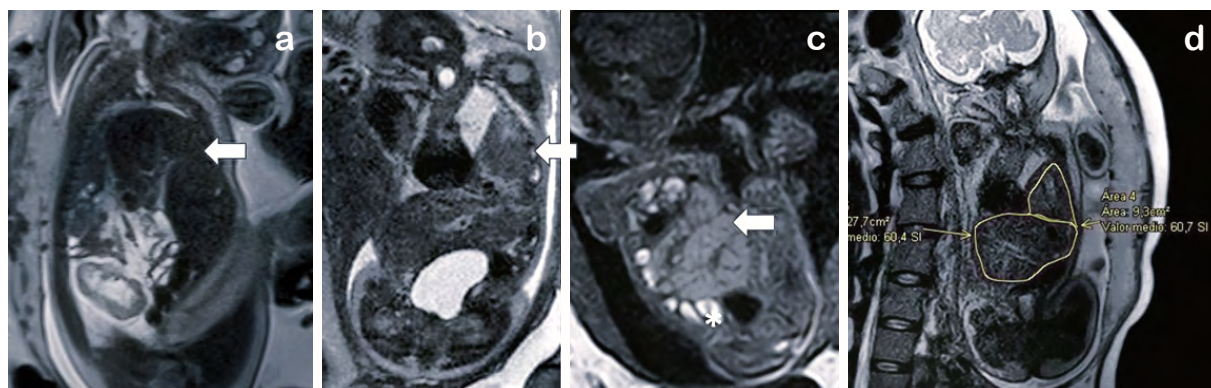


Figure 4. Liver Displacement in Diaphragmatic Hernias by MRI.

In right CDH, the liver is almost always above, and so far, there is no prognostic information available on the degree of herniation. In these, hepatopulmonary fusion has been described as the union of variable degrees of both, ranging from fibrovascular communication to complete fusion. Its preoperative diagnosis is extremely difficult, and in general, it is suspected in the presence of a right CDH with less occupation of the hemithorax than expected. In axial images, the arterial or venous vascular tree distribution is altered in the liver or systemic (see Figure 5). The fused lung has variable degrees of hypoplasia and other anomalies, such as horseshoe lung and areas of dual perfusion. The clinical presentation is similar to CDH and depends on the size of the defect, pulmonary hypoplasia, and associated anomalies (20).

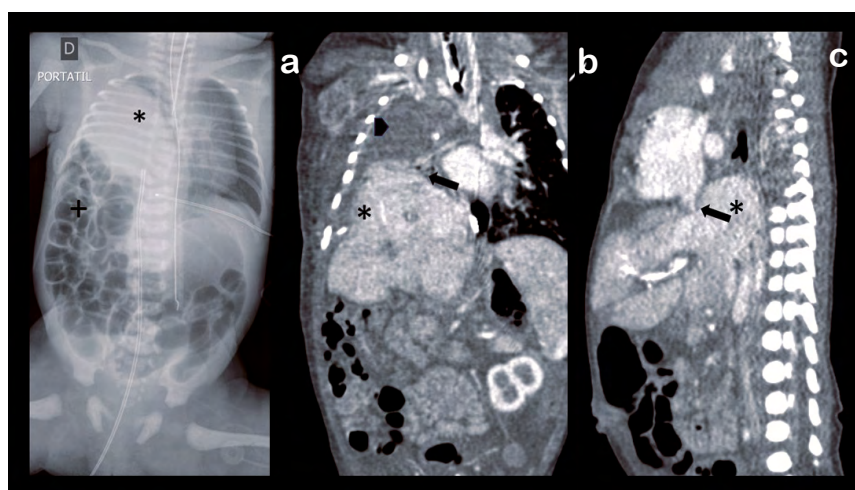


Figure 5. Hepatopulmonary Fusion in Radiography and Tomography.

Gastric ascites: Its exact value as an isolated predictor of morbidity and mortality has yet to be established. MRI is classified according to the degree of ascites and the position of the stomach (21) (see Figure 6). In some studies, the presence of retrocardiac stomach (grade 3) is associated with poor prognosis (22). In addition, the degree of ascites is related to more significant gastrointestinal, respiratory, and neurological morbidity.

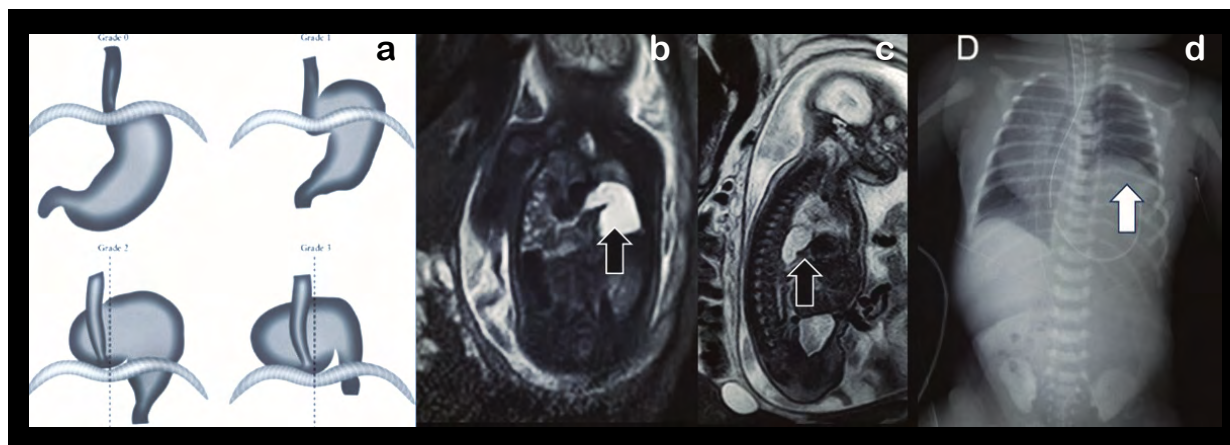


Figure 6. Classification of Gastric Ascension in Fetal MRI.

Hernial sac: 15 to 20% of CDH have a hernial sac. It is related to lower neo and perinatal morbimortality since it generally occurs in more minor defects susceptible to primary repair and with less content. It can be suspected in cases in which a hypoplastic lung displaced superiorly and posteriorly with a meniscus shape is observed in both fMRI and X-ray. The encapsulated appearance of the content on fMRI has a sensitivity of 43% and specificity of 97% (23) (see Figure 7).

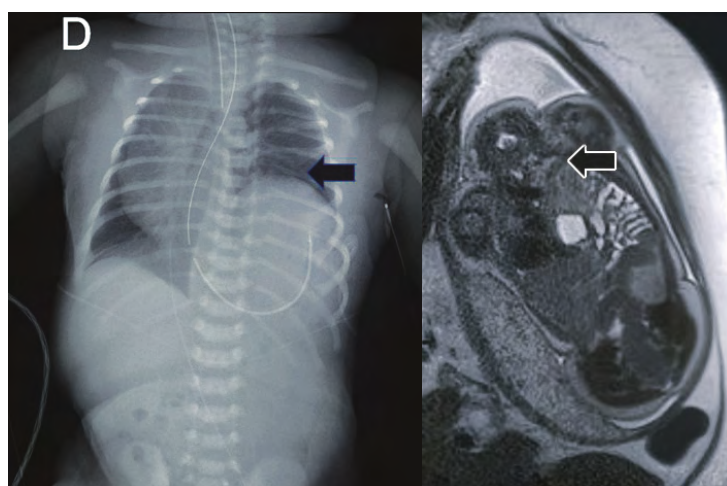


Figure 7. Diaphragmatic Hernia with sac by MRI and X-ray.

Post-natal imaging study

Anteroposterior and lateral thoracoabdominal radiograph with horizontal beam: The most common finding in the immediate neonatal period is complete opacification of the affected hemithorax, accompanied by deviation of the mediastinum to the opposite side. As the air advances, distension of the bowel loops and sometimes the stomach towards the affected hemithorax becomes evident. This imaging technique allows the evaluation of lung expansion and provides a rough estimate of the degree of pulmonary hypoplasia. The absence or minimal presence of gas in the abdomen is characteristic. The anomalous location of the umbilical venous catheters may indicate the presence of a portion of the liver over the diaphragm (24). In addition, the position of the nasogastric tube may be helpful in determining the side of the herniation, especially in cases where there is doubt (see Figure 8).

Thoracoabdominal ultrasound: This technique effectively determines the degree to which solid viscera, especially the liver, have ascended, as well as in measuring the size of the hernial defect and detecting possible vascular complications. It is also used to reevaluate associated malformations that were already known or may have been missed during the prenatal study. In exceptional cases, where there is suspicion of associated anomalies such as congenital pulmonary airway malformations, pulmonary sequestrations, or a strong suspicion of hepatopulmonary fusion, computed tomography is used.

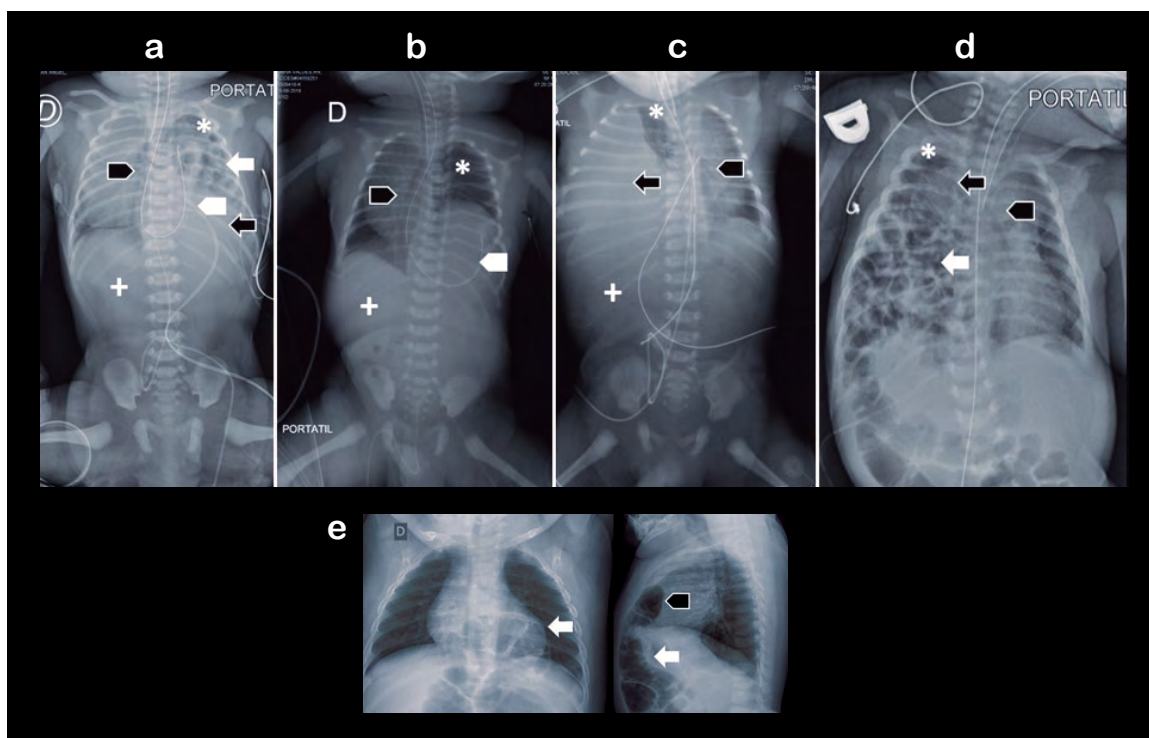


Figure 8. Postnatal Radiographs of Diaphragmatic Hernias.

Serial pre-surgical monitoring: It is common for infants with CDH, like all those with severe neonatal respiratory distress syndrome, to undergo repeated X-ray monitoring. These controls are crucial to evaluate lung expansion, the presence of loop meteorism in the hemithorax, the correct position of the catheters, and the monitoring of the therapies applied, as well as to identify and manage eventual complications that may arise.

RADIOLOGICAL EVALUATION OF TREATMENT

In utero therapy

The current fetal therapy for the treatment of CDH is fetal tracheal occlusion (FETO). The obstruction of the trachea causes fluid retention, which leads to overdistension of the lungs and results in pulmonary hyperplasia with an increased number of alveoli. It is performed through a fetoscopy procedure in which a tracheal balloon is introduced. The results have been promising with a decrease in mortality. Candidates are fetuses with normal karyotype, younger than 28 weeks, and with left intrapleural CDH with poor prognosis (O/E LHR <25% and hepatic ascites) (1). The procedure is performed between 27 and 30 weeks of gestation, the balloon must remain in place for 4 weeks and is removed 2 to 3 weeks before delivery. The main associated risks include premature delivery and the urgent need to remove the tracheal balloon by intrapartum ex-utero treatment if this occurs (25).

Postnatal therapy

Medical treatment is complex and includes the use of assisted ventilation, nitric oxide for treating pulmonary hypertension, and extracorporeal membrane oxygenation (ECMO). The latter consists of a support system for both oxygenation and circulation and is performed through the installation of cannulas that enter via the cervical route, the arterial in the common carotid artery and the venous in the internal jugular vein, with their distal ends in the brachiocephalic trunk and the inferior cavoatrial junction (ECMO veno arterial). This support can be used before, during, or after hernia repair. It should be monitored with serial radiographs in which one can see, in the first instance, complete opacification of both lungs by massive atelectasis and edema, with progressive expansion of the lungs.

The decision on the optimal timing for surgical repair of the hernia depends on the center's experience and the patient's condition. The surgical technique varies widely and depends mainly on the characteristics of the hernia, such as its size and location, and in some cases may require the use of a patch for closure (26), in addition to the preferences of the treating medical team.

POST-SURGICAL CONTROL AND FOLLOW-UP

Immediate

After surgery for congenital diaphragmatic hernias, it is expected to observe the presence of a hydropneumothorax on

immediate postoperative radiographs. This finding should not be confused with a pathologic pneumothorax. The hypoplastic lung is expected to expand gradually, leading to a decrease in pneumothorax and an increase in pleural effusion. This pleural effusion tends to become organized and marginally and posteriorly distributed over time. As this process progresses, a gradual decrease in the displacement of mediastinal structures is observed. During this phase, it is crucial to pay special attention to any sudden increase in the amount of pleural effusion and/or pneumothorax, as this may require drainage to facilitate adequate lung expansion (see Figures 9a and 9b).

Long-term follow-up

Children diagnosed with congenital diaphragmatic hernias often require prolonged stays in intensive care units, where imaging controls are common practice. In their long-term follow-up, multiple thoracoabdominal radiographs and brain and abdominal ultrasounds are usually performed. Complications frequently evaluated by imaging include reherniation, gastrointestinal

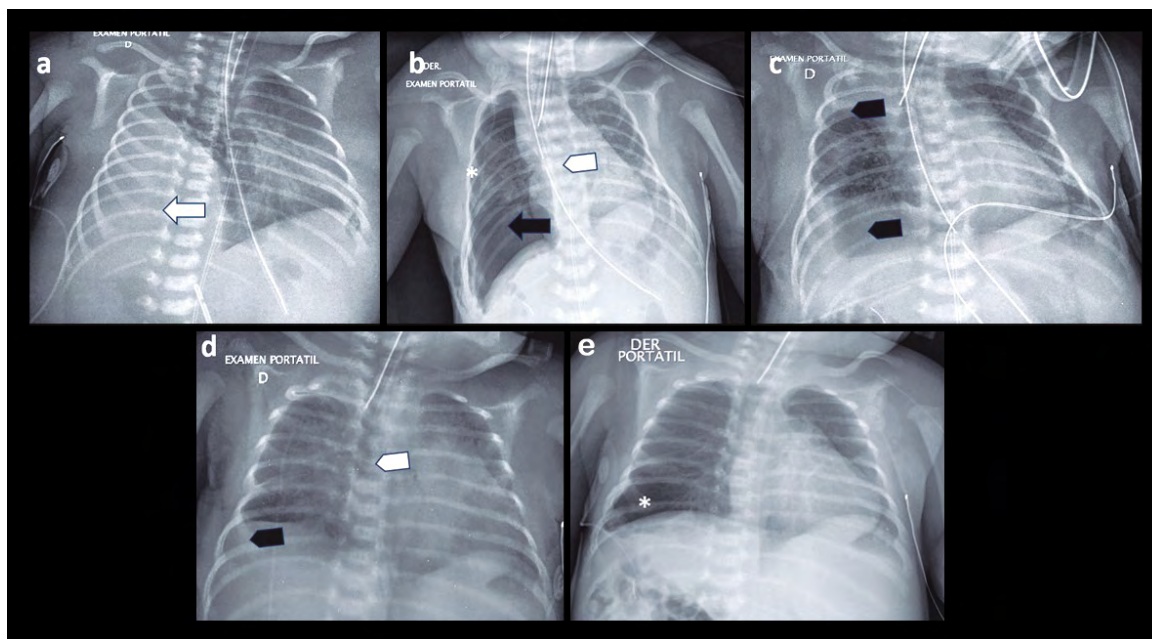


Figure 9a. Postoperative evolution of diaphragmatic hernias.

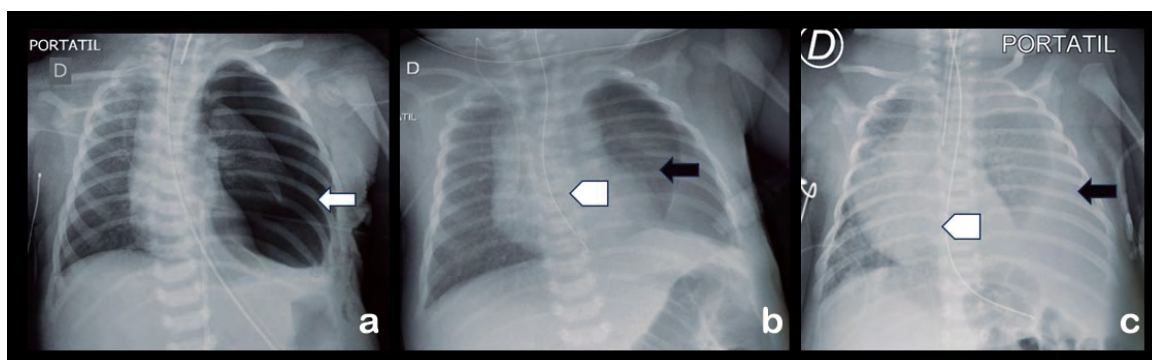


Figure 9b. Post-surgical complications in diaphragmatic hernias.

problems, musculoskeletal abnormalities, and pulmonary sequelae. This ongoing follow-up is crucial to identify and manage promptly any complications that may arise after treatment.

Reherniation: The incidence of reherniation in patients with CDH varies considerably according to different studies, with rates ranging from 2.4% to 65%. It has been observed that 47% of cases of re-herniation occur before the first year of life and 76% before two years of age (27). The risk factors most associated with re-herniation include the size of the original hernial defect, the severity of the child's condition, the surgical technique employed, and the need for diaphragmatic and abdominal patching. Re-herniation may occur at the same site as the original hernia or in the hiatus area in cases of left CDH (28). Since most

reherniation is asymptomatic, serial radiographic monitoring is essential (29). On radiographs, reherniation can be identified by an alteration in the diaphragmatic contour visible in both projections. This allows for omental ascent in small hernias or of viscera, intestinal loops or stomach. In cases where the diagnosis is unclear, computed tomography with contrast medium or ultrasound can be used to confirm it (see Figure 10).

Gastrointestinal alterations: Gastroesophageal reflux affects up to 52.7% of postoperative left CDH children in the year of life due to anatomical factors specific to the diaphragmatic defect, esophageal shortening, dysmotility, and post-surgical changes. It is more frequent in CDH with hepatic and/or gastric ascites. This condition can lead to failure to thrive, pulmonary infections, aspiration, and permanent discomfort

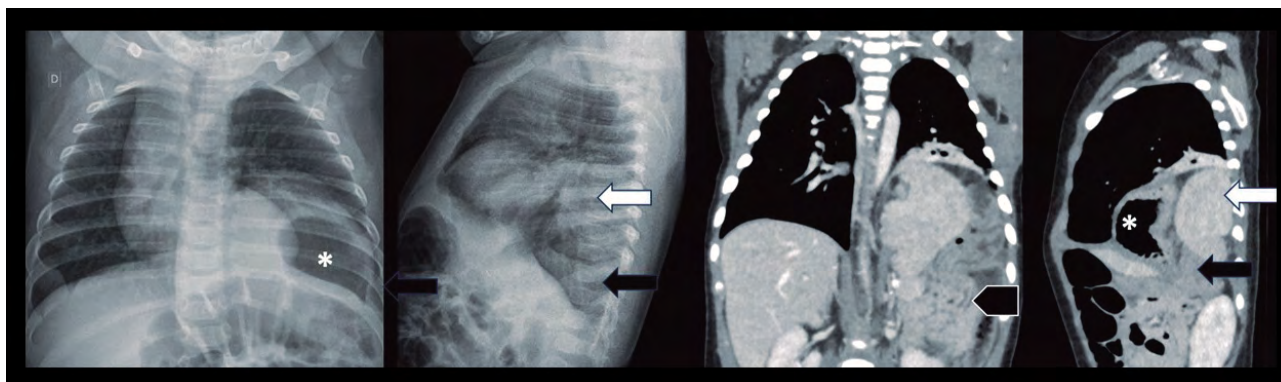


Figure 10. Rx and CT of repaired diaphragmatic hernia.

in older children (26). The performance of antireflux surgery at the same time as hernia correction is controversial.

Intestinal obstruction has a prevalence of between 4 to 21% of children can have an obstruction. In general, the diagnosis is made with anteroposterior and lateral abdominal radiographs, where the dilatation of the loops, formation of levels, and complications such as perforation or pneumatosis are observed. The clinical management of this problem is surgical.

Musculoskeletal abnormalities: Asymmetric pectus excavatum or hypoplasia of one hemithorax affects up to 47% of patients at 2 years of life, more frequent on the operated side, and generally progressive. Post-surgical changes may also be evident. These alterations can determine restrictive pulmonary pathology in addition to the esthetic sequelae (28). On the other hand, scoliosis affects up to 13% of patients, is mild to moderate, progressive, and has a later onset in life (28).

Pulmonary sequelae: These are present in most children and determine a large part of the long-term morbidity. They are multifactorial, on the one hand, they are consequences of hypoplasia of the affected lung, and to a lesser extent of the contralateral lung, with structural alterations of the bronchi and alveoli due to less development of them and anomalies in the development of the pulmonary vasculature, which constitutes a type of interstitial disease due to growth anomalies (29). This can also be associated with chronic pulmonary damage due to mechanical ventilation and intercurrent infections. Radiological abnormalities include hyperlucency of the hypoplastic lung with decreased volume and vascularization (29). These CT findings manifest as areas of air trapping, perfusion mosaic, chronic appearance changes, and pleural thickening in the affected area (see Figure 11). They are also accompanied by pulmonary hypertension, and

in pulmonary function tests, it has a restrictive or obstructive pattern (29).

Conclusion

Congenital diaphragmatic hernias are serious pathologies. Imaging has a fundamental role in all stages, from prenatal diagnosis through immediate postnatal and preoperative evaluation and follow-up both in hospitalization and post-discharge ambulatory controls. It is essential to have

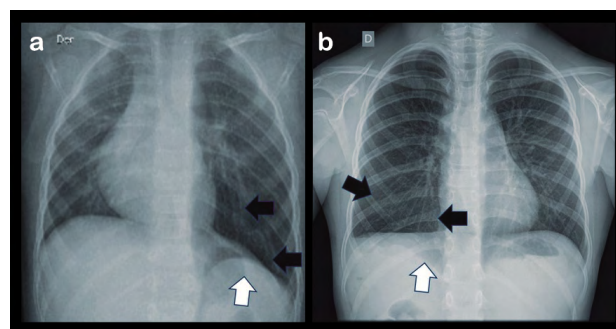


Figure 11. Chest X-ray after Diaphragmatic Hernia Surgery.

knowledge of the usual findings in all these stages and the most frequent complications to provide the necessary support to the treating team to make decisions that result in increased survival and decreased complications for these children.

Authors' contribution: All authors approved the version that was finally submitted. All authors are responsible for all aspects of the manuscript.

Financing: This study was self-financed.

Conflicts of interest: The authors declare no conflicts of interest.

REFERENCES

- Puri P, Nakazawa N. Congenital Diaphragmatic Hernia. En: Puri P, Höllwarth M, editores. *Pediatric Surgery* [Internet]. Berlin, Heidelberg: Springer; 2009 [citado el 19 de septiembre de 2023]. p. 307–13. Disponible en: https://link.springer.com/chapter/10.1007/978-3-540-69560-8_31
- Goldshore MA, Hedrick HL. Congenital Diaphragmatic Hernia. En: Mattei P, editor. *Fundamentals of Pediatric Surgery* [Internet]. Cham: Springer International Publishing; 2022 [citado el 19 de septiembre de 2023]. p. 773–80. Disponible en: https://link.springer.com/chapter/10.1007/978-3-031-07524-7_80
- Akinkuotu AC, Cruz SM, Cass DL, Lee TC, Cassidy CI, Mehollin-Ray AR, et al. An evaluation of the role of concomitant anomalies on the outcomes of fetuses with congenital diaphragmatic hernia. *J Pediatr Surg*. 2016;51(5):714-7. doi: 10.1016/j.jpedsurg.2016.02.008
- Politis MD, Bermejo-Sánchez E, Canfield MA, Contiero P, Cragan JD, Dastgiri S, et al. Prevalence and mortality in children with congenital diaphragmatic hernia: a multicountry study. *Ann Epidemiol*. 2021;56:61-9.e3. doi: 10.1016/j.annepidem.2020.11.007
- Mehollin-Ray AR, Cassidy CI, Cass DL, Olutoye OO. Fetal MR imaging of congenital diaphragmatic hernia. *Radiographics*. 2012;32(4):1067-84. doi: 10.1148/rg.324115155
- Mehollin-Ray AR. Congenital diaphragmatic hernia. *Pediatr Radiol*. 2020;50(13):1855-71. doi: 10.1007/s00247-020-04718-w
- Kline-Fath BM. Current advances in prenatal imaging of congenital diaphragmatic [corrected] hernia. *Pediatr Radiol*. 2012;42 Suppl 1:S74-90. doi: 10.1007/s00247-011-2183-3
- Burgos CM, Frenckner B, Luco M, Harting MT, Lally PA, Lally KP, et al. Prenatally versus postnatally diagnosed congenital diaphragmatic hernia - Side, stage, and outcome. *J Pediatr Surg*. 2019;54(4):651-5. doi: 10.1016/j.jpedsurg.2018.04.008
- Kosiński P, Wielgoś M. Congenital diaphragmatic hernia: pathogenesis, prenatal diagnosis and management - literature review. *Ginek Pol*. 2017;88(1):24-30. doi: 10.5603/GP.a2017.0005
- Duess JW, Zani-Ruttenstock EM, Garriboli M, Puri P, Pierro A, Hoellwarth ME. Outcome of right-sided diaphragmatic hernia repair: a multicentre study. *Pediatr Surg Int*. 2015;31(5):465-71. doi: 10.1007/s00383-015-3695-y
- Jani J, Nicolaides KH, Keller RL, Benachi A, Peralta CF, Favre R, et al. Observed to expected lung area to head circumference ratio in the prediction of survival in fetuses with isolated diaphragmatic hernia. *Ultrasound Obstet Gynecol*. 2007 Jul;30(1):67-71. doi: 10.1002/uog.4052
- Perinatology.com [Internet]. [citado 19 de septiembre de 2023]. Calculators. The calculator below may be used to estimate the LHR, the o/e LHR, and the QLI. Disponible en: <https://perinatology.com/calculators/LHR.htm>
- Lee W, Krisko A, Shetty A, Yeo L, Hassan SS, Gotsch F, Mody S, Gonçalves LF, Romero R. Non-invasive fetal lung assessment using diffusion-weighted imaging. *Ultrasound Obstet Gynecol*. 2009;34(6):673-7. doi: 10.1002/uog.7446
- Keller TM, Rake A, Michel SC, Seifert B, Wissner J, Marincek B, et al. MR assessment of fetal lung development using lung volumes and signal intensities. *Eur Radiol*. 2004;14(6):984-9. doi: 10.1007/s00330-004-2256-x
- Rypens F, Metens T, Rocourt N, Sonigo P, Brunelle F, Quere MP, et al. Fetal lung volume: estimation at MR imaging-initial results. *Radiology*. 2001;219(1):236-41. doi: 10.1148/radiology.219.1.r01ap18236.
- Meyers ML, Garcia JR, Blough KL, Zhang W, Cassidy CI, Mehollin-Ray AR. Fetal Lung Volumes by MRI: Normal Weekly Values From 18 Through 38 Weeks' Gestation. *AJR Am J Roentgenol*. 2018;211(2):432-8. doi: 10.2214/AJR.17.19469
- Zamora IJ, Olutoye OO, Cass DL, Fallon SC, Lazar DA, Cassidy CI, et al. Prenatal MRI fetal lung volumes and percent liver herniation predict pulmonary morbidity in congenital diaphragmatic hernia (CDH). *J Pediatr Surg*. 2014;49(5):688-93. doi: 10.1016/j.jpedsurg.2014.02.048
- Ferguson DM; Congenital Diaphragmatic Hernia Study Group. Hepatopulmonary fusion: A rare variant of congenital diaphragmatic hernia. *J Pediatr Surg*. 2020;55(9):1903-7. doi: 10.1016/j.jpedsurg.2019.09.037
- Kitano Y, Okuyama H, Saito M, Usui N, Morikawa N, Masumoto K, et al. Re-evaluation of stomach position as a simple prognostic factor in fetal left congenital diaphragmatic hernia: a multicenter survey in Japan. *Ultrasound Obstet Gynecol*. 2011;37(3):277-82. doi: 10.1002/uog.8892
- Masahata K, Yamoto M, Umeda S, Nagata K, Terui K, Fujii M, et al. Prenatal predictors of mortality in fetuses with congenital diaphragmatic hernia: a systematic review and meta-analysis. *Pediatr Surg Int*. 2022;38(12):1745-1757. doi: 10.1007/s00383-022-05232-w
- Zamora IJ, Mehollin-Ray AR, Sheikh F, Cassidy CI, Williams JL, Lee TC, et al. Predictive Value of MRI Findings for the Identification of a Hernia Sac in Fetuses With Congenital Diaphragmatic Hernia. *AJR Am J Roentgenol*. 2015;205(5):1121-5. doi: 10.2214/AJR.15.14476
- Taylor GA, Atalabi OM, Estroff JA. Imaging of congenital diaphragmatic hernias. *Pediatr Radiol*. 2009;39(1):1-16. doi: 10.1007/s00247-008-0917-7
- Van Calster B, Benachi A, Nicolaides KH, Gratacos E, Berg C, Persico N, et al. The randomized Tracheal Occlusion To Accelerate Lung growth (TOTAL)-trials on fetal surgery for congenital diaphragmatic hernia: reanalysis using pooled data. *Am J Obstet Gynecol*. 2022;226(4):560.e1-24. doi: 10.1016/j.ajog.2021.11.1351
- Jiménez JA, Eixarch E, DeKoninck P, Bennini JR, Devlieger R, Peralta CF, et al. Balloon removal after fetoscopic endoluminal tracheal occlusion for congenital diaphragmatic hernia. *Am J Obstet Gynecol*. 2017;217(1):78.e1-11. doi: 10.1016/j.ajog.2017.02.041
- Macchini F, Raffaelli G, Amodeo I, Ichino M, Encinas JL, Martinez L, et al. Recurrence of Congenital Diaphragmatic Hernia: Risk Factors, Management, and Future Perspectives. *Front Pediatr*. 2022;10:823180. doi: 10.3389/fped.2022.823180
- Zahn KB, Schaible T, Rafat N, Weis M, Weiss C, Wessel L. Longitudinal Follow-Up With Radiologic Screening for Recurrence and Secondary Hiatal Hernia in Neonates With Open Repair of Congenital Diaphragmatic Hernia-A Large Prospective, Observational Cohort Study at One Referral Center. *Front Pediatr*. 2021;9:796478. doi: 10.3389/fped.2021.796478
- Jancelewicz T, Chiang M, Oliveira C, Chiu PP. Late surgical outcomes among congenital diaphragmatic hernia (CDH) patients: why long-term follow-up with surgeons is recommended. *J Pediatr Surg*. 2013;48(5):935-41. doi: 10.1016/j.jpedsurg.2013.02.005
- Semple T, Winant AJ, Lee EY. Childhood Interstitial Lung Disease: Imaging Guidelines and Recommendations. *Radiol Clin North Am*. 2022;60(1):83-111. doi: 10.1016/j.rcl.2021.08.009
- Pennaforte T, Rakza T, Sfeir R, Aubry E, Bonneville M, Fayoux P, et al. Hernie de couple diaphragmatique : devenir respiratoire et vasculaire pulmonaire. *Rev Mal Respir*. 2012;29(2):337-46. doi: 10.1016/j.rmr.2011.07.009