

## REVIEW

# Radiological assessment of the position of lines and tubes in children: a pictorial review

Mario Sinti-Ycochea<sup>1</sup>, Mario F. Chirinos Gambarini<sup>2</sup>, Vania Candy Ccuno Peralta<sup>2</sup>, Carlos F. Ugas-Charcape<sup>2</sup>

<sup>1</sup> Servicio de Diagnóstico por Imágenes, Hospital III Emergencias Grau, Lima, Perú

<sup>2</sup> Servicio de Diagnóstico por Imágenes, Instituto Nacional de Salud del Niño San Borja, Lima, Perú

**ABSTRACT**

This pictorial review addresses the correct positioning of medical devices used in pediatrics, such as arterial and venous umbilical catheters, central venous catheters, pulmonary arterial catheters (Swan-Ganz), nasogastric, orogastric, and nasoduodenal tubes, endotracheal tubes, tracheostomy tubes, pleural drainage tubes, and cardiac pacemakers. It focuses on the importance of identifying the proper placement of these devices to prevent complications and improve clinical care. The correct positions and complications associated with malpositions are described, emphasizing the use of radiographs for the evaluation and monitoring of these devices in pediatric patients.

**Keywords:** Medical Devices; Radiology; Catheter; Stents; Digital Radiography; X-rays; Multidetector Computed Tomography; Pediatrics (Source: MeSH)

**Cite as:**


Sinti-Ycochea M, Chirinos Gambarini MF, Ccuno Peralta VC, Ugas-Charcape CF. Radiological assessment of the position of lines and tubes in children: a pictorial review. *Investig Innov Clin Quir Pediatr.* 2023;1(2):26-9. doi:10.59594/iicqp.2023.v1n2.61

**Corresponding author:**


Mario Sinti-Ycochea  
Address: Avenida República de Colombia 525, Lima, Perú  
Telephone: +51996699441  
E-mail: mariosinti99x@gmail.com

**ORCID iDs**


Mario Sinti-Ycochea

 <https://orcid.org/0000-0003-0656-3552>


Mario F. Chirinos Gambarini

 <https://orcid.org/0000-0002-5512-5439>

Vania Candy Ccuno Peralta

 <https://orcid.org/0000-0002-2244-5022>

Carlos F. Ugas-Charcape

 <https://orcid.org/0000-0002-8380-3276>

**Received** : 28/07/2023

**Accepted** : 09/11/2023

**Published** : 29/12/2023



This publication is licensed under a Creative Commons Attribution 4.0 International License.

Copyright © 2023, The authors

## Evaluación radiológica de la posición de sondas y catéteres en pediatría: una revisión pictórica

**RESUMEN**

Esta revisión pictórica tiene objetivo generar una guía visual mediante imágenes médicas para evaluar la correcta posición de dispositivos médicos utilizados en pediatría, como catéteres umbilicales arterial y venoso, catéter venoso central, catéter pulmonar arterial (Swan-Ganz), sondas nasogástricas, orogástricas y nasoduodenales, tubos endotraqueales, tubos de traqueostomía, tubos de drenaje pleural y marcapasos cardiacos. Se enfoca en la importancia de identificar la ubicación adecuada de estos dispositivos para prevenir complicaciones y mejorar la atención clínica. Se describen las posiciones correctas y las complicaciones asociadas con las malposiciones, con énfasis en el uso de radiografías para la evaluación y seguimiento de estos dispositivos en pacientes pediátricos.

**Palabras clave:** Dispositivos Médicos; Radiología; Catéteres; Stents; Radiografía Digital; Rayos X; Tomografía Computarizada Multidetector; Pediatría (Fuente: DeCS)

## INTRODUCTION

The insertion and management of vascular lines and the placement of enteral and tracheal tubes are invasive procedures that demand skill and precision. Improper placement of these devices can result in clinically significant complications. Peripheral line catheterization is common in hospitals, with approximately 70% of hospitalized patients using some intravenous device (1). Specifically in pediatrics, a study in a Neonatal Intensive Care Unit (NICU) revealed that up to 48% of patients had a peripherally inserted central venous catheter (2). It is relevant to mention that these central venous catheters are often placed in urgent situations, and a control radiograph is frequently not performed immediately after insertion. This may result in malpositions undetected by clinicians (3,4,5). The literature on complications due to catheter malposition in pediatrics is limited and focuses mainly on puncture site problems. Of the complications related to peripherally inserted central venous catheters, approximately 40% are due to infections (14.4%) and occlusions (13.4%) (6).

It is important to correctly identify the position of these devices to avoid complications. This pictorial review aims to provide a visual guide to assess the correct positioning of medical devices used in pediatrics. This guide is intended for radiologists, residents, and attending physicians who require this information.

#### UMBILICAL ARTERIAL CATHETER

This device is commonly used in Neonatal Intensive Care Units (NICU) to monitor blood pressure and administer medications and fluids. Its route is through the umbilical artery, internal iliac artery, common iliac artery, and finally, the aorta. On radiographs, an arterial umbilical catheter is considered well positioned if its distal end is between vertebral levels D6 and D9 for a high position (7) or between L3 and L5 for a low position (8) (Figure 1A). Clinically, the high position is preferred because it is associated with fewer complications (9), such as vascular compromise (10), including gluteoperoneal necrosis associated with sciatic nerve palsy due to thrombosis of the inferior gluteal artery (11). A malposition is identified when the distal end is not located at these levels, which can lead to complications such as the location of the distal end in the aortic arch, brachiocephalic artery, subclavian artery, celiac trunk, superior mesenteric artery, renal artery, or contralateral common iliac artery (11,12).

#### UMBILICAL VENOUS CATHETER

This catheter is used in the NICU for medication and fluids infusion, blood collection for analysis, and central venous pressure monitoring (13). Its route follows the umbilical vein, the umbilical recess, crosses the left portal vein, reaches the ductus venosus, and ends in the inferior vena cava. According to the radiograph, the catheter should be positioned correctly when the distal end is located at the junction between the inferior vena cava and the right atrium (inferior cavoatrial junction) or in the lower portion of the right atrium (8) (Figure 1B). Malpositions may include high locations in the superior vena cava, internal jugular vein, pulmonary artery, and the left atrium through a patent foramen ovale (14). Sometimes, the catheter may form a loop in the umbilical recess and return into the umbilical vein or follow the path of a portal branch (Figure 1C). If the catheter remains in the system, it may cause portal thrombosis with late symptoms (13,14).

Since radiographs are the product of image superimposition, frontal and lateral (or tangential) incidence can be requested to better evaluate these catheters. The umbilical arterial catheter travels caudally until it reaches the internal iliac artery and ascends through the abdominal aorta. In contrast, the umbilical venous catheter enters through the umbilical region reaching the hepatic silhouette, without traveling caudally, and finally locating itself in the topography of the inferior vena cava (8,11).

#### CENTRAL VENOUS CATHETER

Central venous catheters, Port catheters, and peripherally inserted central venous catheters (PICC) are used in pediatrics. The proper positioning of a central venous catheter depends on its entry route. If introduced through

the upper extremities, its distal end should be placed in the superior vena cava or superior cavoatrial junction (Figure 2A). If introduced through the lower extremities, it should be in the inferior vena cava (15). An important point to consider in radiographs is that the superior cavoatrial junction is at the level of the tracheobronchial angle and the carina (16) (Figure 2B). Malpositions of the distal end may include locations in the right atrium (Figure 2C) and in non-central veins such as the brachiocephalic, subclavian, axillary, or saphenous veins, which may cause endocardial lesions, pleural effusion, pneumothorax, phlebitis, thrombosis and infections (8,11).

#### PULMONARY ARTERIAL CATHETER (SWAN-GANZ)

This catheter, which includes an inflatable balloon, is mainly used for hemodynamic monitoring in critical situations. It crosses the internal jugular vein, superior vena cava, right atrium, and right ventricle and reaches the pulmonary artery. According to radiography, the optimal distal end position is in the right or left pulmonary artery and may extend to the proximal portion of a lobar branch. A key aspect is that the catheter tip should never go beyond the pulmonary hilum (8,16) (Figure 2D); otherwise, it is considered malposition. For prolonged periods, misplacement in a distal arterial segment can cause pulmonary infarction, especially if the balloon remains inflated. It is crucial to watch for new radiopacities on control radiographs (8). Other complications include damage to the tricuspid valve by intracardiac loops (16), pulmonary artery pseudoaneurysm, and rupture.

#### NASOGASTRIC, OROGASTRIC, AND NASODUODENAL TUBES

These are tubes used for drainage and administration of medications or nutrition. The correct position of the nasogastric and orogastric tubes evaluated by radiography includes the tube going down the midline of the thorax with the distal end located 10 cm below the gastroesophageal junction (17). Note that the lateral holes of the probe should be located below the diaphragm (8) (Figure 3A). Additionally, nasoduodenal probes present a metallic tip that ideally should be located distal to the pylorus projected on the topography of the duodenum (Figure 3B). Among the complications of malposition are intravascular penetration, perforation of hollow viscera, atelectasis due to bronchial location, and, more rarely, intracranial penetration in post-operative patients with choanal atresia or maxillofacial trauma (17).

#### ENDOTRACHEAL TUBE

It is used in children with acute respiratory distress or in Anesthesiology. The correct position to evaluate in X-rays is characterized by the distal end in the midpoint between the clavicular heads and the carina (8) (Figures 3C and 3D). It must be considered that the endotracheal tube can move (+/- 2 cm) with the flexion and extension of the neck (18, 19).

#### TRACHEOSTOMY TUBE

They are commonly used for patients with prolonged respiratory compromise. Unlike the endotracheal tube, this one does not move with neck flexion or extension. In radiographs, the correct position is determined by the flexible part of the tube, which must be located in the air column of

the trachea (8) (Figure 3E). For some authors, radiographic evaluation after tracheostomy tube placement is unnecessary since it does not offer additional information to what the clinical evaluation provides, and this examination should only be requested at the treating physician's discretion in case of suspected complications (20). A recent study mentions significant differences between the distance of the distal end of the tube above the carina shown by radiography versus direct tracheoscopy, the latter being more recommendable since radiographic measurements tend to be overestimated (21).

#### PLEURAL DRAINAGE TUBE

They are placed in the anterosuperior thorax region for pneumothorax drainage and in the posterobasal region for pleural effusion drainage. Like the feeding tubes, they have lateral holes which, together with the distal end of the tube, should be located medial to the pleural space on chest radiographs; however, according to the literature, radiography is a less reliable method of study compared to computed tomography for the evaluation of thoracic drainage (8, 22) (Figure 4A, 4B, 4C and 4D).

#### PACEMAKER

Two types of cardiac pacemakers are used in pediatrics: temporary and permanent. Temporary pacemakers have two removable epicardial leads with typical dermal knots visible on radiographs. Permanent pacemakers have leads that can be placed transvenously with endocardial fixation or epicardially during open surgery. The distal lead is easily assessed by chest radiography. It must be located in the right atrium, right ventricle, or coronary sinus (Figure 4E) and has a typical corkscrew appearance recognizable by radiography (8, 14).

#### Conclusion

It is essential to highlight the importance of this paper, as it underscores the critical role of the radiologist in the interpretation of radiographs of patients with various medical devices. These include a wide range of vascular catheters, drainage, tracheal and enteral tubes, ventricular assist devices, and implantable electronic devices of greater complexity (Figure 5). This publication is of great value to clinical and surgical specialists who need a practical and efficient reference for imaging evaluation in urgent or emergency medical situations. In addition, this guide is encouraged to promote research on the incidence of complications due to the malposition of these catheters and probes, which is crucial for developing appropriate corrective strategies in the institutional setting.

**Authorship contributions:** MSY and CFUC conceptualized, designed, and conducted the study's research methodology. MSY, MFCG, VCCP, and CFUC drafted, reviewed, and approved the final version of the manuscript.

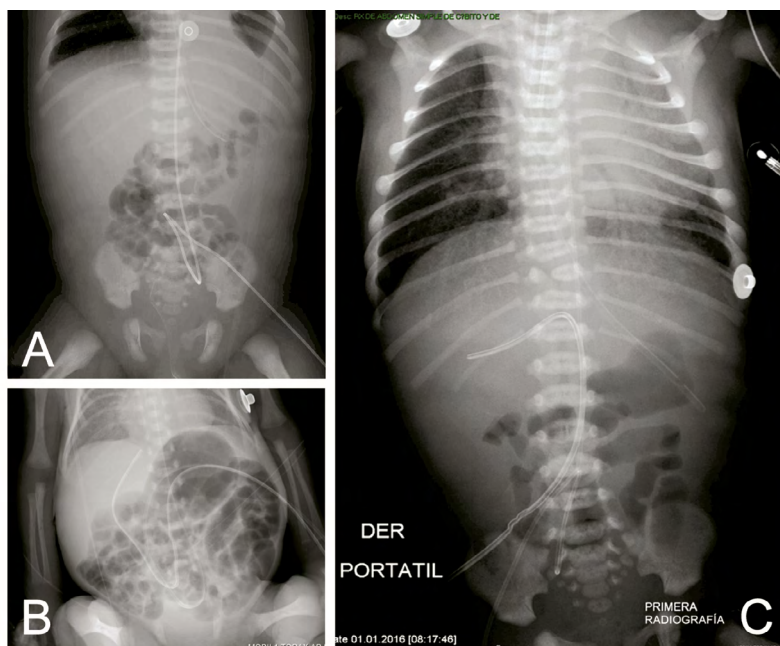
**Financing:** Self-financed

**Conflicts of interest:** The authors declare no conflicts of interest.

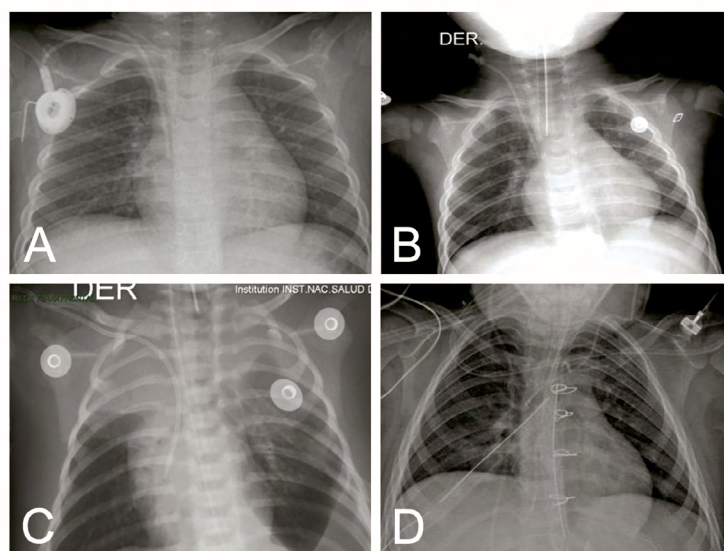
## REFERENCES

1. Instituto Nacional de Salud del Niño San Borja (INSNSB). Guía de Procedimientos de Enfermería: Inserción, Mantenimiento y Retiro de Catéter Venoso Central [Internet]. Lima: INSN SB; 2021 [citado el 27 de julio de 2023]. Disponible en: <https://www.insnsb.gob.pe>
2. Aguilar Ronceros LF, Abad Bernardo FC, Chávez Rodríguez MN, La Rosa Solórzano JG, Loayza Escobar KY, et al. Utilización del catéter venoso central de inserción periférica en la Unidad de Cuidados Intensivos Neonatales del Instituto Nacional de Salud Del Niño Breña, 2017–2019. *An Fac Med.* 2022;83(3):223–7. doi: 10.15381/anales.v83i3.22500
3. Galimany Masclans J, Berlanga Olalla R, Pernas Canadell JC. La radiografía de tórax en la unidad de cuidados intensivos. *Imagen Diagn.* 2013;4(1):13–9. doi: 10.1016/j.imadi.2011.12.001
4. Blas Macedo J. Cateterismo venoso central: complicaciones atribuidas al extremo distal del catéter. *Med Crit* [Internet]. 2004 [citado el 28 de julio de 2023];18(4):123–6. Disponible en: <https://www.medigraphic.com/cgi-bin/new/resumen.cgi?IDARTICULO=1595>
5. Castro Hernández GO, Figueroa S, Víctor G, Leo Méndez M. Experiencia en catéteres venosos centrales y periféricos en el Centro Estatal de Cancerología, Veracruz, México, 2006–2009. *Rev Med UV* [Internet]. 2010 [consultado el 27 de julio de 2023]. Disponible en: [https://www.uv.mx/rm/num\\_anteriores/revmedica\\_vol10\\_num1/articulos/experiencia.pdf](https://www.uv.mx/rm/num_anteriores/revmedica_vol10_num1/articulos/experiencia.pdf)
6. Flores Moreno, M. Factores de riesgo asociados con complicaciones que obligaron al retiro de catéteres venosos centrales de inserción periférica en un hospital pediátrico de tercer nivel. *Bol Med Hosp Infant Mex.* 2017;74(4):289–94. doi: 10.1016/j.bmhixm.2017.03.010
7. Finn D, Kinoshita H, Livingstone V, Dempsey EM. Optimal line and tube placement in very preterm neonates: An audit of practice. *Children (Basel).* 2017;4(11). doi: 10.3390/children4110099
8. Liszewski MC, Daltro P, Lee EY. Back to fundamentals: Radiographic evaluation of thoracic lines and tubes in children. *AJR Am J Roentgenol.* 2019;212(5):988–96. doi: 10.2214/AJR.18.20704
9. Hospital Nacional Docente Madre-Niño “San Bartolomé”. Guía de Procedimiento Asistencial Cateterismo Umbilical Venoso Arterial [Internet]. Lima: HONADOMANI SB; 2021 [citado el 27 de julio de 2023]. Disponible en: <http://sieval.sanbartolome.gob.pe/transparencia/Publicacion2021/Direccion/RD%20115%20SB%202021.pdf>
10. Government of Western Australia, Child and Adolescent Health Service. Guideline Central Line Imaging in Neonates: Radiographic Views, and Acceptable Line Positions [Internet]. Perth: CAHS; 2021 [citado el 27 de julio de 2023]. Disponible en: <https://www.cahs.health.wa.gov.au/-/media/HSPs/CAHS/Documents/Health-Professionals/Neonatology-guidelines/Central-Line-Imaging-in-Neonates-Radiographic-Views-and-Acceptable-Line-Positions.pdf>
11. Fuentealba T I, Retamal C A, Ortiz C G, Pérez R M. Evaluación radiológica de catéteres en UCI neonatal. *Rev Chil Pediatr.* 2014;85(6):724–30. doi: 10.4067/s0370-41062014000600011
12. Barrington KJ. Umbilical artery catheters in the newborn: effects of position of the catheter tip. *Cochrane Database Syst Rev.* 2000;(2):CD000505. doi: 10.1002/14651858.CD000505
13. Valdés Vázquez NO, Valdés López A. Colocación y posicionamiento de catéteres umbilicales. *Archivos de Investigación Materno Infantil.* 2020;11(2):66–76. doi: 10.35366/101553
14. Hermansen MC, Hermansen MG. Intravascular catheter complications in the neonatal intensive care unit. *Clin Perinatol.* 2005;32(1):141–56. doi: 10.1016/j.clp.2004.11.005
15. Beluffi G, Perotti G, Sileo C, Fiori P, Figar T, Stronati M. Central venous catheters in premature babies: radiological evaluation, malpositioning

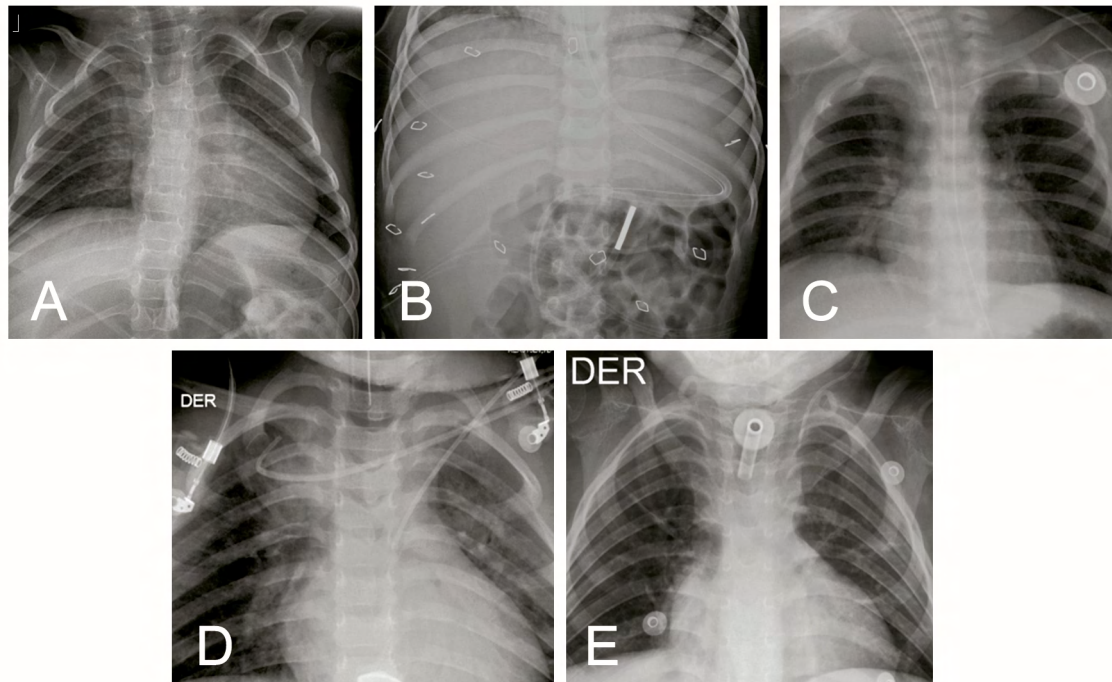
- and complications. *Pediatr Radiol.* 2012;42(8):1000–8. doi: 10.1007/s00247-012-2391-5
16. Sakhthivel MK, Bosemani T, Bacchus L, Pamuklar E. Malpositioned lines and tubes on chest radiograph - A concise pictorial review. *J Clin Imaging Sci.* 2020;10(66):66. doi: 10.25259/JCIS\_170\_2020
  17. Pillai JB, Vegas A, Brister S. Thoracic complications of nasogastric tube: review of safe practice. *Interact Cardiovasc Thorac Surg.* 2005;4(5):429–33. doi: 10.1510/icvts.2005.109488
  18. Das SK, Choupoo NS, Haldar R, Lahkar A. Transtracheal ultrasound for verification of endotracheal tube placement: a systematic review and meta-analysis. *Can J Anaesth.* 2015;62(4):413–23. doi: 10.1007/s12630-014-0301-z
  19. Goodman LR, Conrardy PA, Laing F, Singer MM. Radiographic evaluation of endotracheal tube position. *AJR Am J Roentgenol.* 1976;127(3):433–4. doi: 10.2214/ajr.127.3.433
  20. Tobler WD Jr, Mella JR, Ng J, Selvam A, Burke PA, Agarwal S. Chest X-ray after tracheostomy is not necessary unless clinically indicated. *World J Surg.* 2012;36(2):266–9. doi: /10.1007/s00268-011-1380-4
  21. Keane A, Saadi RA, Slonimsky E, Wilson M, May J. Comparison of tracheoscopy and portable chest X-Ray in the evaluation of infant tracheostomy tube position. *Int J Pediatr Otorhinolaryngol.* 2021;141(110566):110566. doi: 10.1016/j.ijporl.2020.110566
  22. Lim K-E, Tai S-C, Chan C-Y, Hsu Y-Y, Hsu W-C, Lin B-C, et al. Diagnosis of malpositioned chest tubes after emergency tube thoracostomy: is computed tomography more accurate than chest radiograph? *Clin Imaging.* 2005;29(6):401–5. doi: 10.1016/j.clinimag.2005.06.032



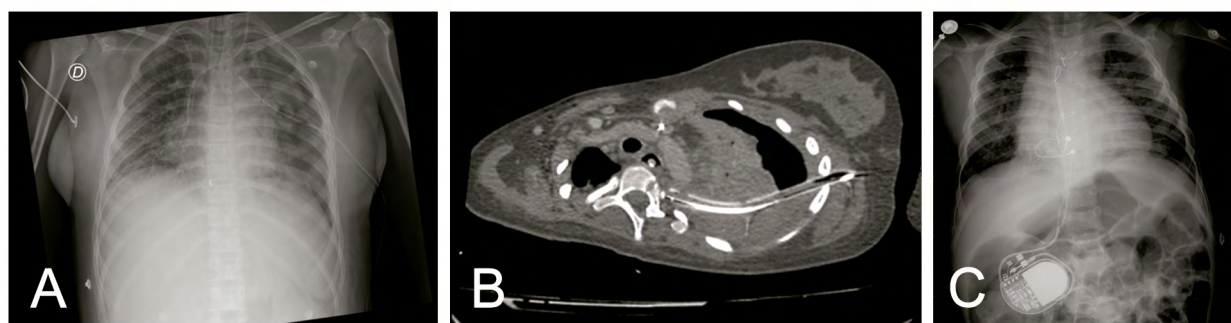
**Figure 1.** **A.** Recumbent abdominal x-ray of a 3-month-old male patient with left diaphragmatic hernia. An optimally positioned umbilical arterial catheter with a distal end at the level of D9 is observed. **B.** Abdominal X-ray in a recumbent position of a premature newborn with necrotizing enterocolitis and with an umbilical venous catheter correctly positioned at the level of the inferior cavoatrial junction. **C.** Anteroposterior chest-abdomen x-ray: A female infant, 1-month-old, with cardiomegaly and D10 vertebra with butterfly morphology, presents with a poorly positioned umbilical venous catheter with a distal tip projecting into the right branch of the portal vein, and a poorly positioned umbilical arterial catheter with a distal end at the level of D4-D5.



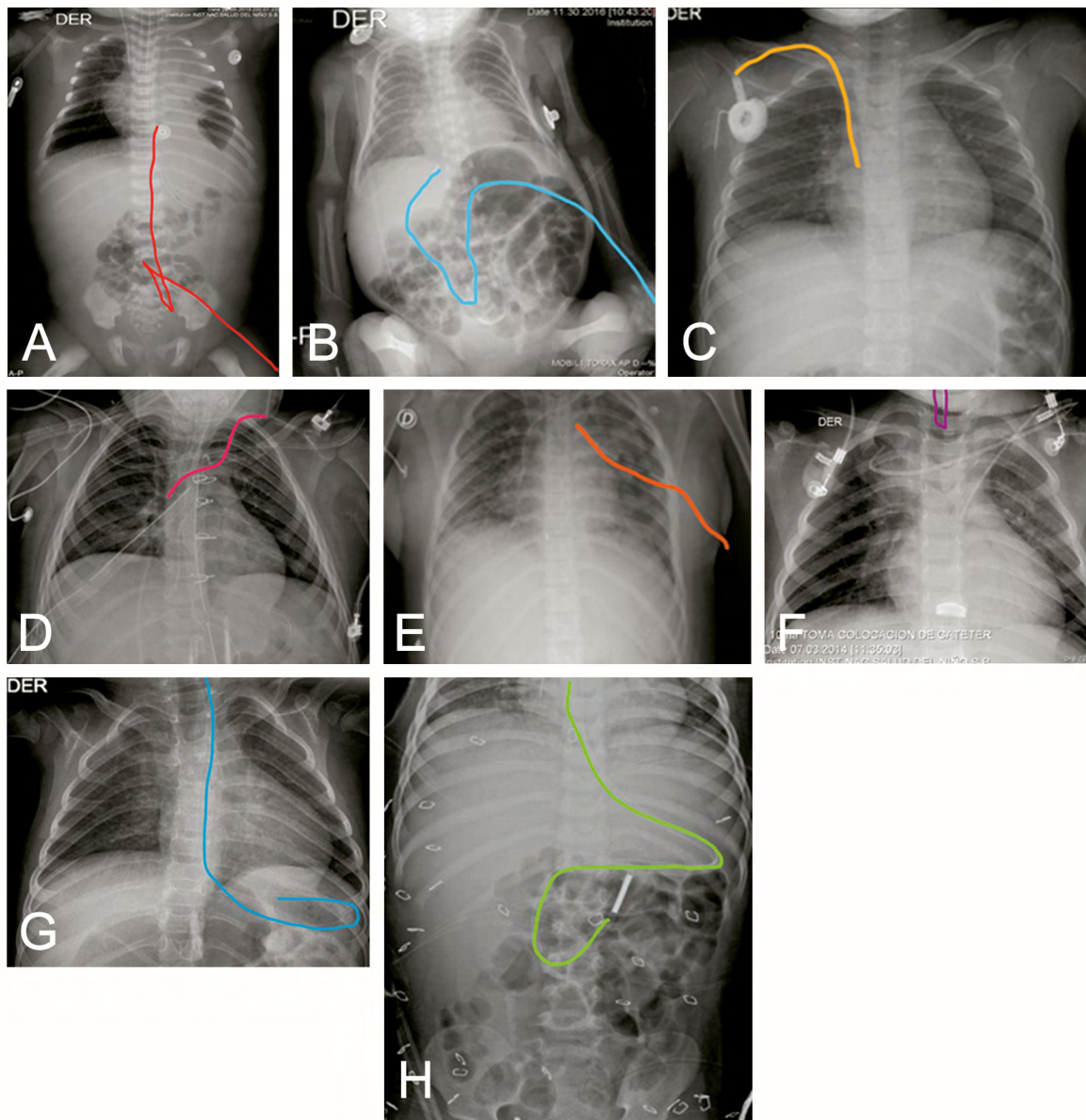
**Figure 2.** **A.** Anteroposterior chest x-ray: 6-year-old girl with a history of acute lymphoblastic leukemia undergoing chemotherapy with suspected neutropenic colitis. The Port catheter is correctly located at the level of the superior vena cava (white arrow). **B.** Anteroposterior chest x-ray of a 10-month-old patient with a grade II burn and a right central venous catheter correctly located at the upper cavoatrial junction. **C.** Anteroposterior chest x-ray: 10-day-old male newborn with left pleural effusion and atelectasis of the right upper lobe who presents with a poorly placed right central venous catheter with a distal tip projecting into the right atrium. **D.** 5-year-old patient post-operation for aortic stenosis with the presence of a Swan-Gans catheter with a distal tip located at the level of the left branch of the pulmonary artery.



**Figure 3.** A. Anteroposterior chest x-ray of a 21-month-old patient hospitalized for pneumonia and wearing a correctly positioned nasogastric tube with a distal end in the gastric chamber. B. Abdominal x-ray in the supine position of a 20-month-old patient hospitalized for a burn and carrying a nasoduodenal tube correctly located in the typical topography of the duodenum and its characteristic metallic-dense distal tip. C. Anteroposterior chest x-ray of a 5-week-old patient with duodenal stenosis carrying a correctly located endotracheal tube with a distal end between the clavicular heads and the carina. D. Anteroposterior chest x-ray: 5-year-old boy with a diagnosis of Acute Lymphoblastic Leukemia and carrying an endotracheal tube poorly located above the clavicular heads. E. Anteroposterior chest x-ray of a 4-year-old patient with a history of burns with a tracheostomy tube correctly positioned at the level of the tracheal air column.



**Figure 4.** 16-year-old adolescent with acute lymphoblastic leukemia with hydropneumothorax. A. An anteroposterior chest radiograph shows a pleural drainage tube with a distal end in the upper third of the left hemithorax; lateral holes of the tube are located medial to the pleural space. B. Computed tomography of the chest in the axial reconstruction of the mediastinal window shows a pleural drainage tube with a malpositioned distal tip projected into the left paravertebral region. C. Decubitus abdominal radiograph of a 3-year-old patient with double outlet right ventricle and carrier of temporary pacemaker with the classic appearance of epicardial pacing leads placed by open surgery (due to the presence of sternotomy surgical clips) projected into the right atrium.



**Figure 5.** Summary of the correct position of medical devices. **A.** Umbilical arterial catheter with a correct high position at the D6 to D10 level and a correct low position at the L3 to L5 level (the red line shows the path). **B.** The umbilical venous catheter is in an optimal position at the inferior cavoatrial junction (the light blue line shows the path). **C.** Central venous catheter, Porth catheter, and peripherally inserted central venous catheter (PICC) have a correct position at the level of the upper cavoatrial junction (the yellow tracing shows the path of a Porth catheter). **D.** Swan-Ganz catheter has a distal end in a normal position projected at the left or right pulmonary artery level or proximal to any lobar artery (the pink tracing shows the catheter path projected at the level of the left pulmonary artery). **E.** Pleural drainage tube with distal end and lateral holes inside the pleura (the orange tracing shows the path). **F.** The endotracheal tube was correctly positioned with a distal end between the carina and clavicular heads (purple tracing shows the contours of the tube). **G.** The orogastric tube must be located in the gastric chamber (the blue line shows the probe's path). **H.** The nasoduodenal tube, which has a metallic end, must be projected into the duodenum (the green line shows the probe's path).